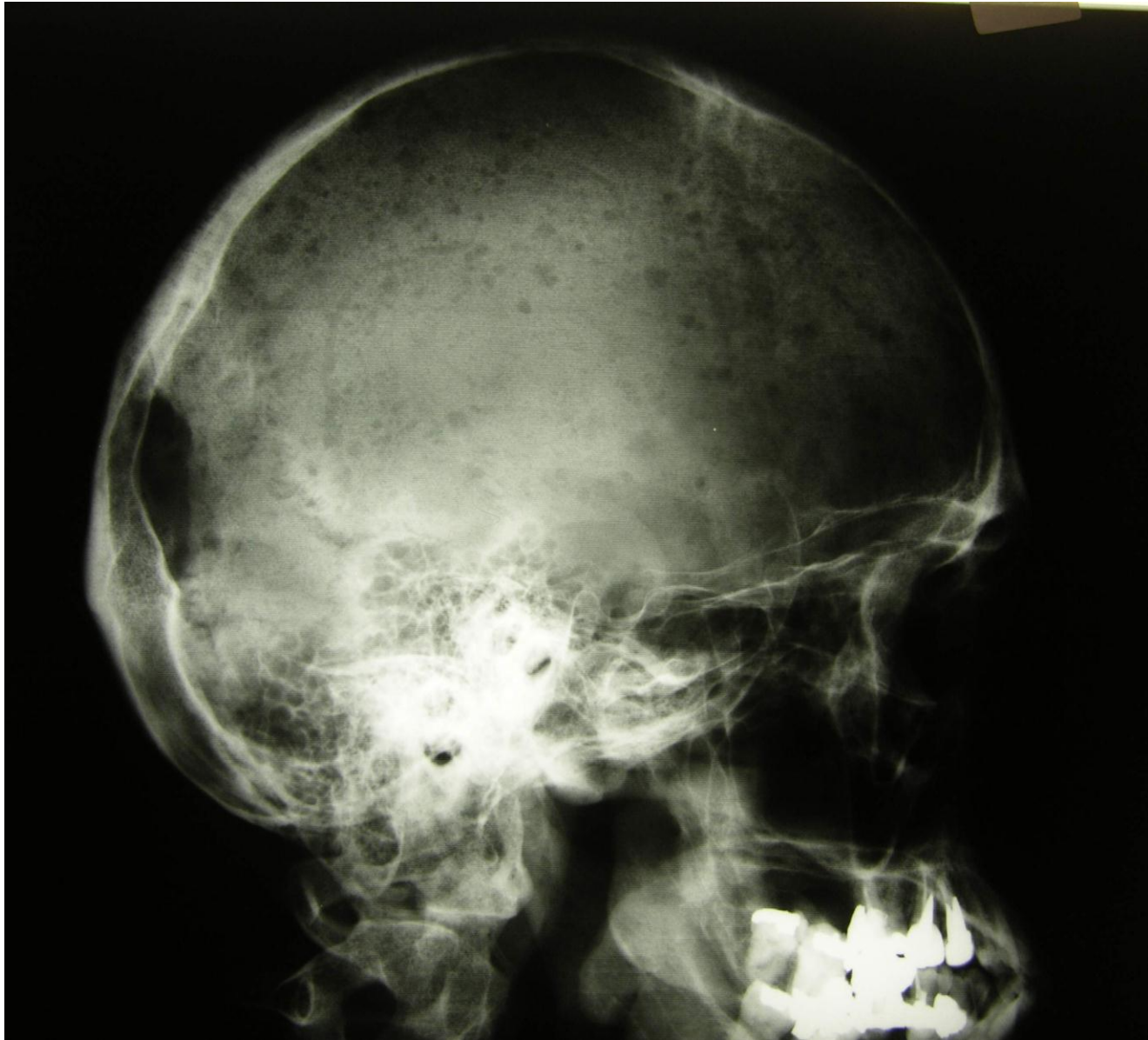
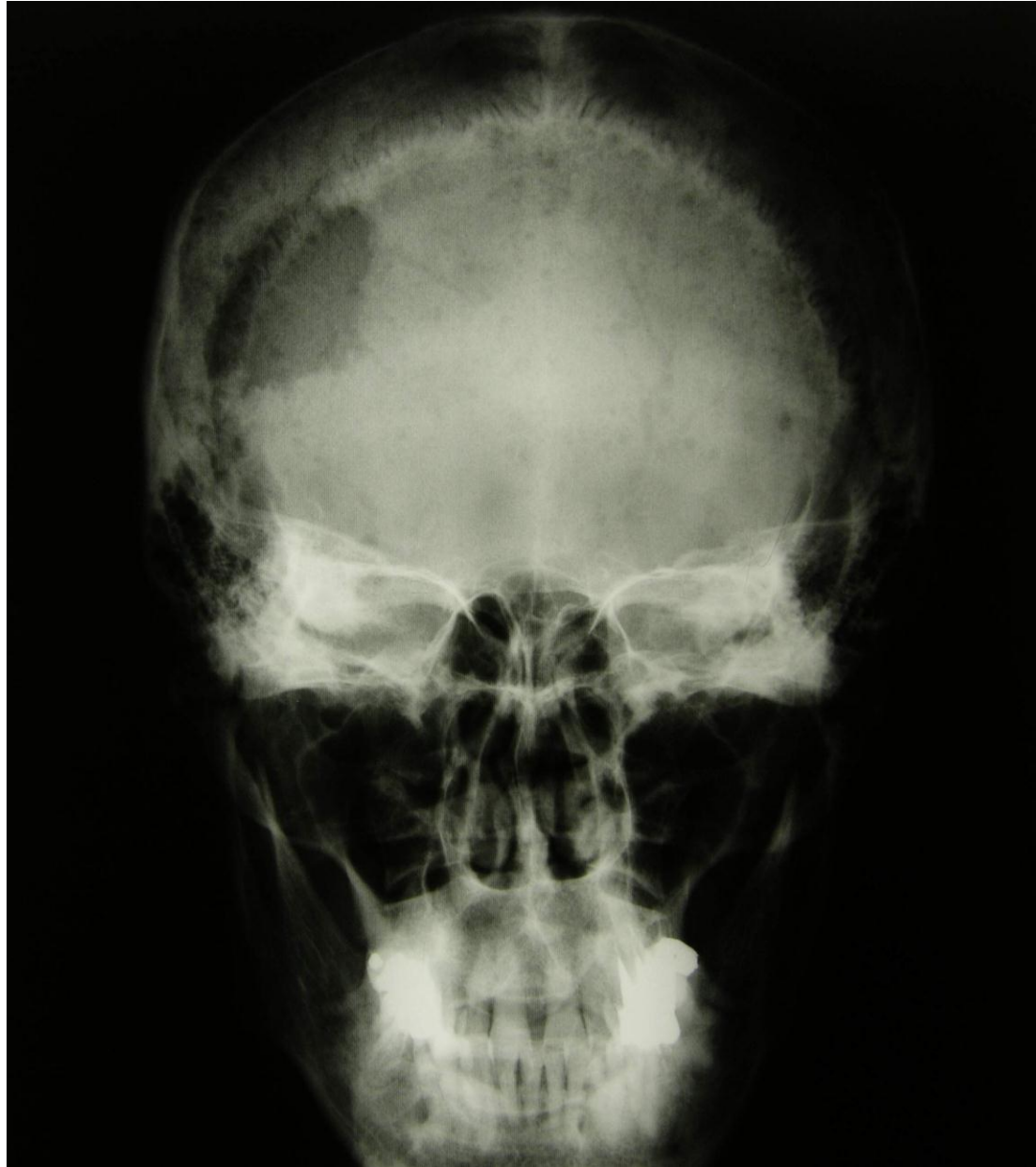
RTG 2

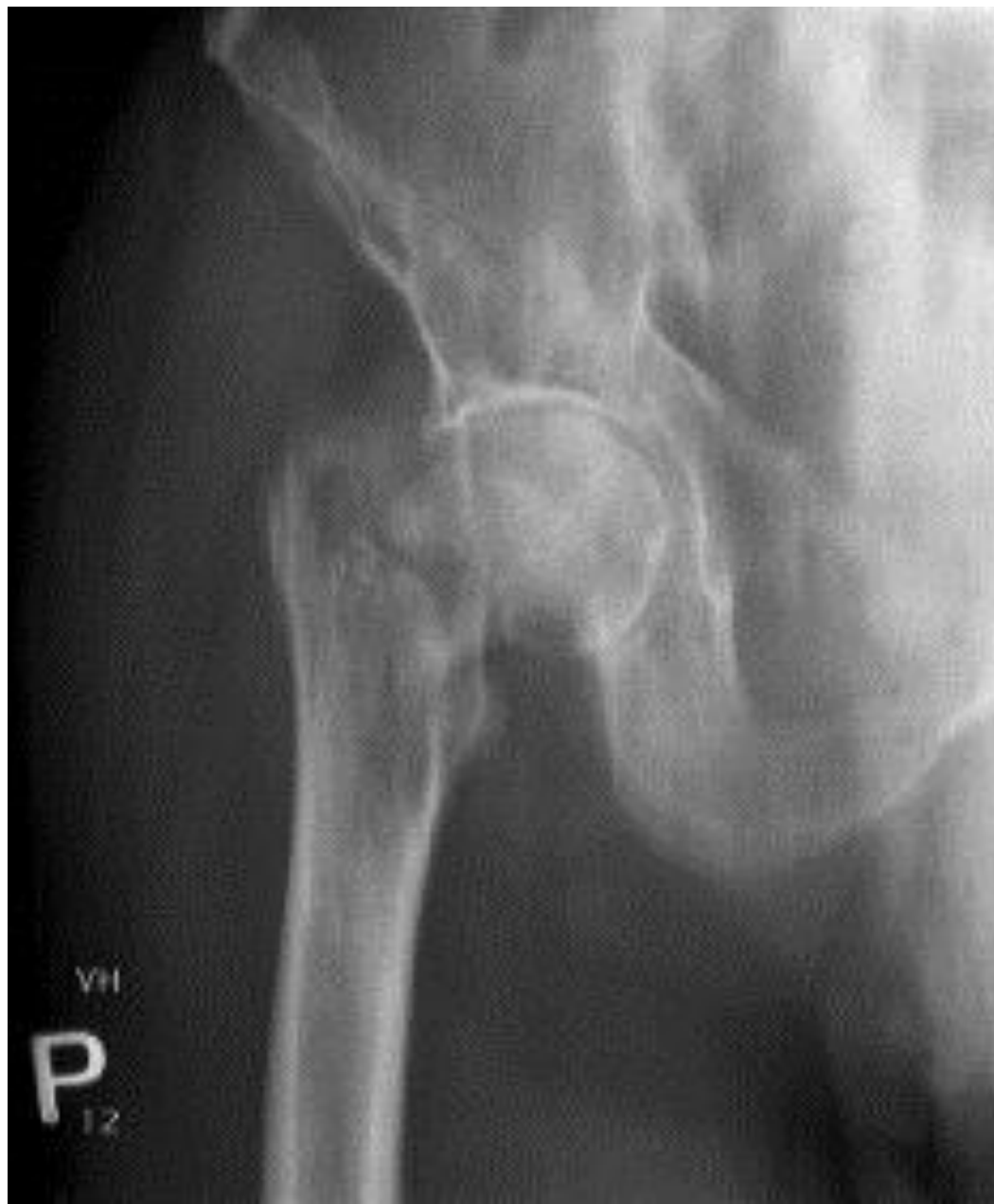MM skull lateral



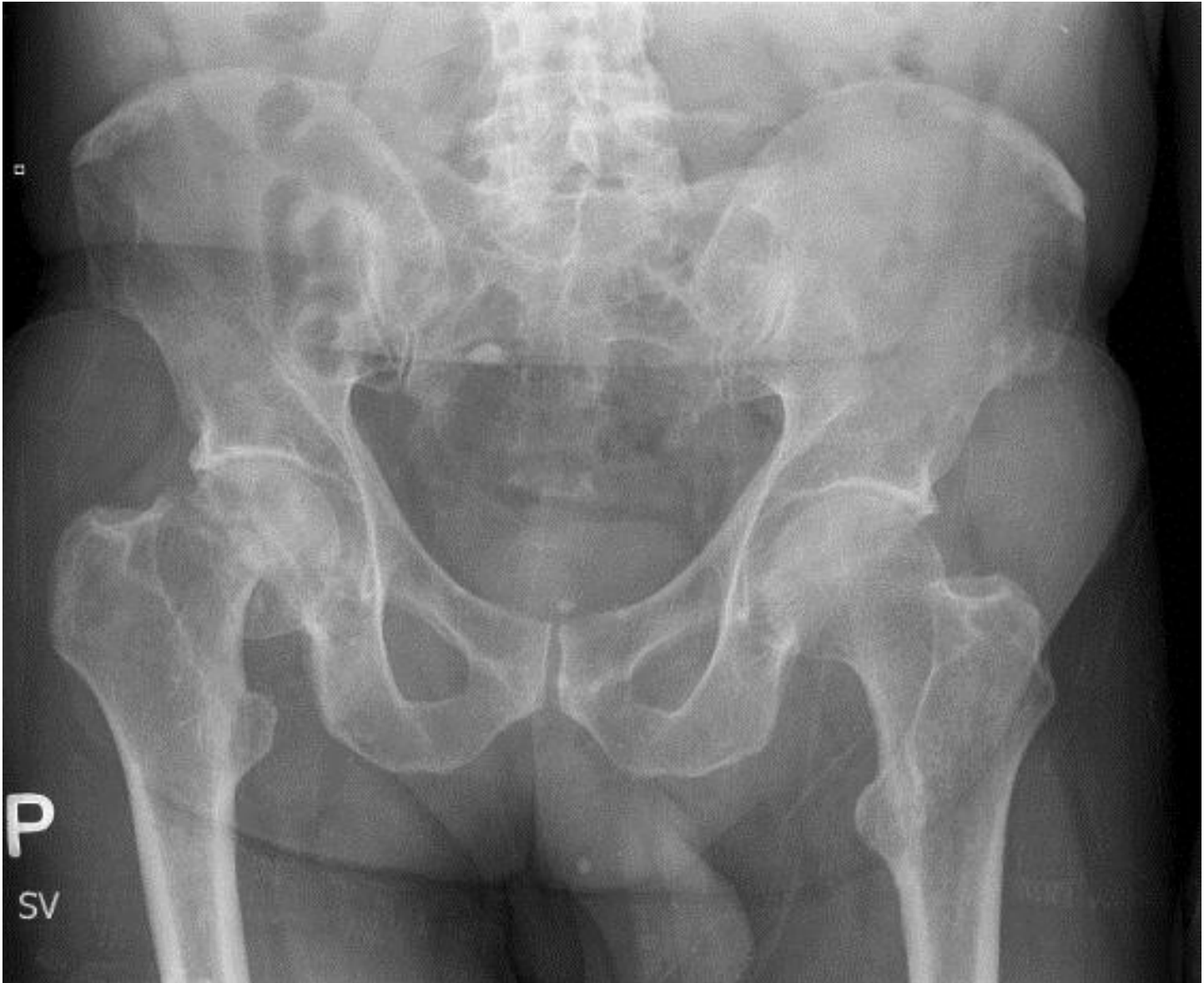MM skull AP



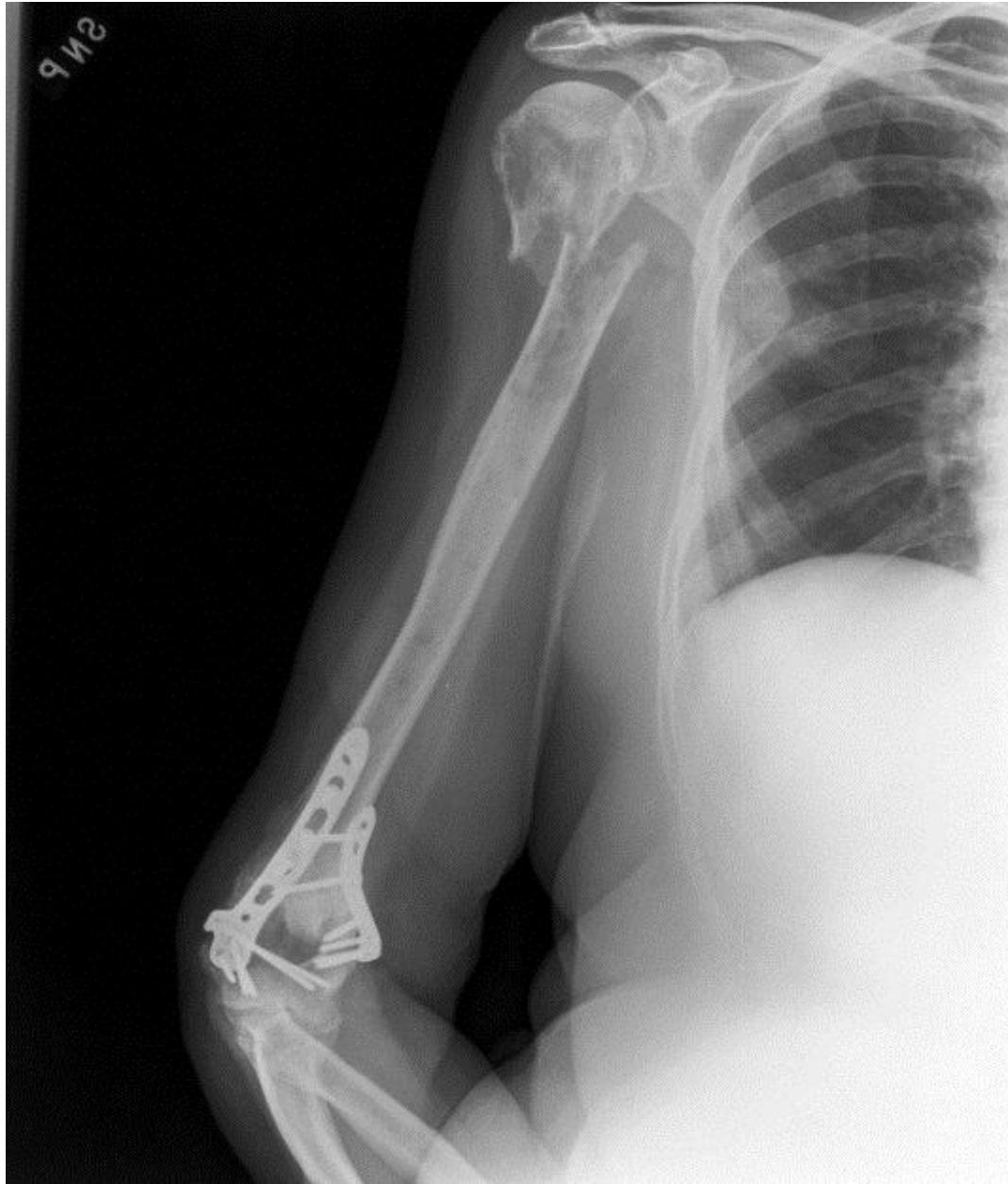MM fract. of femur



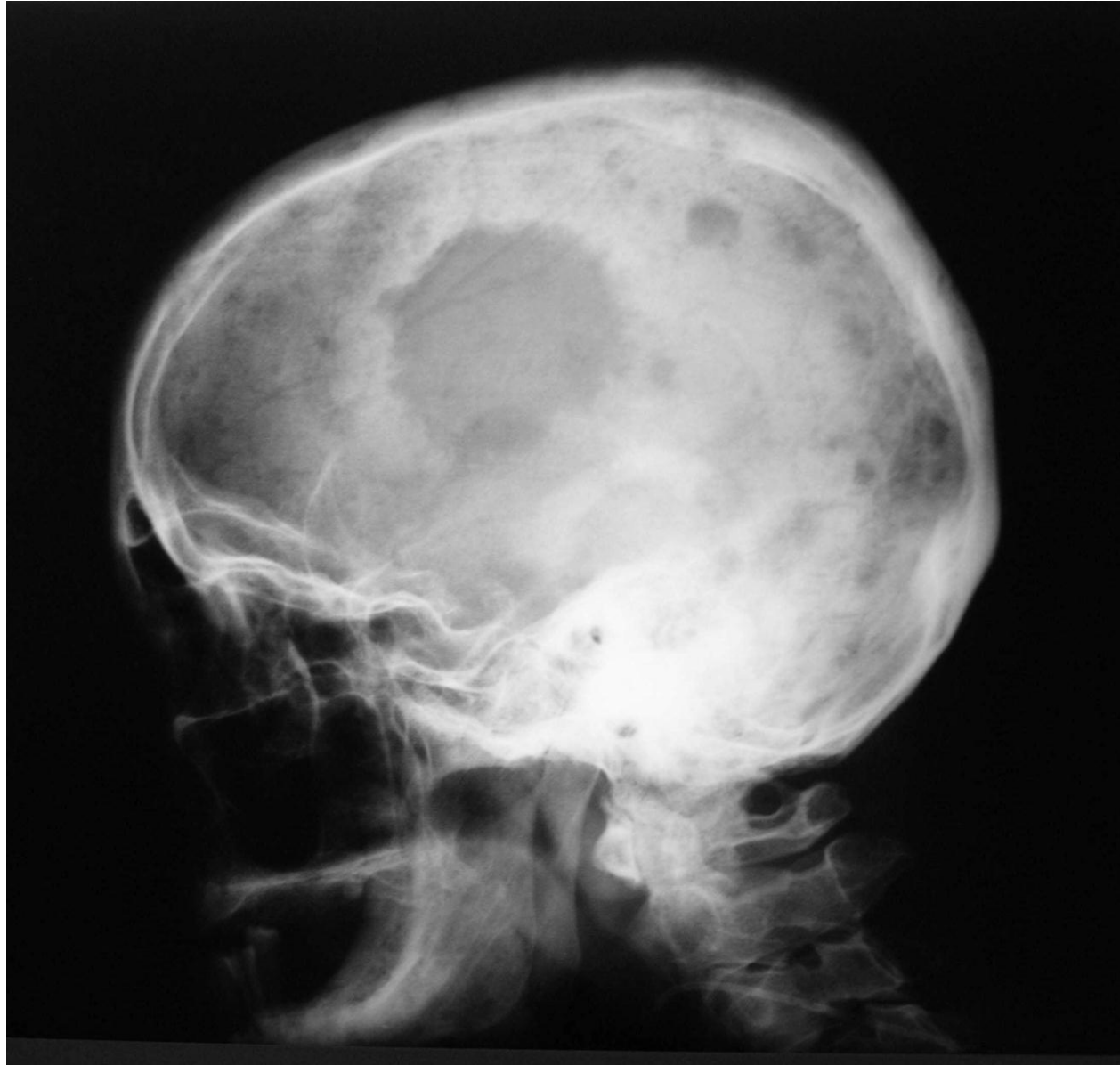MM fract of femur



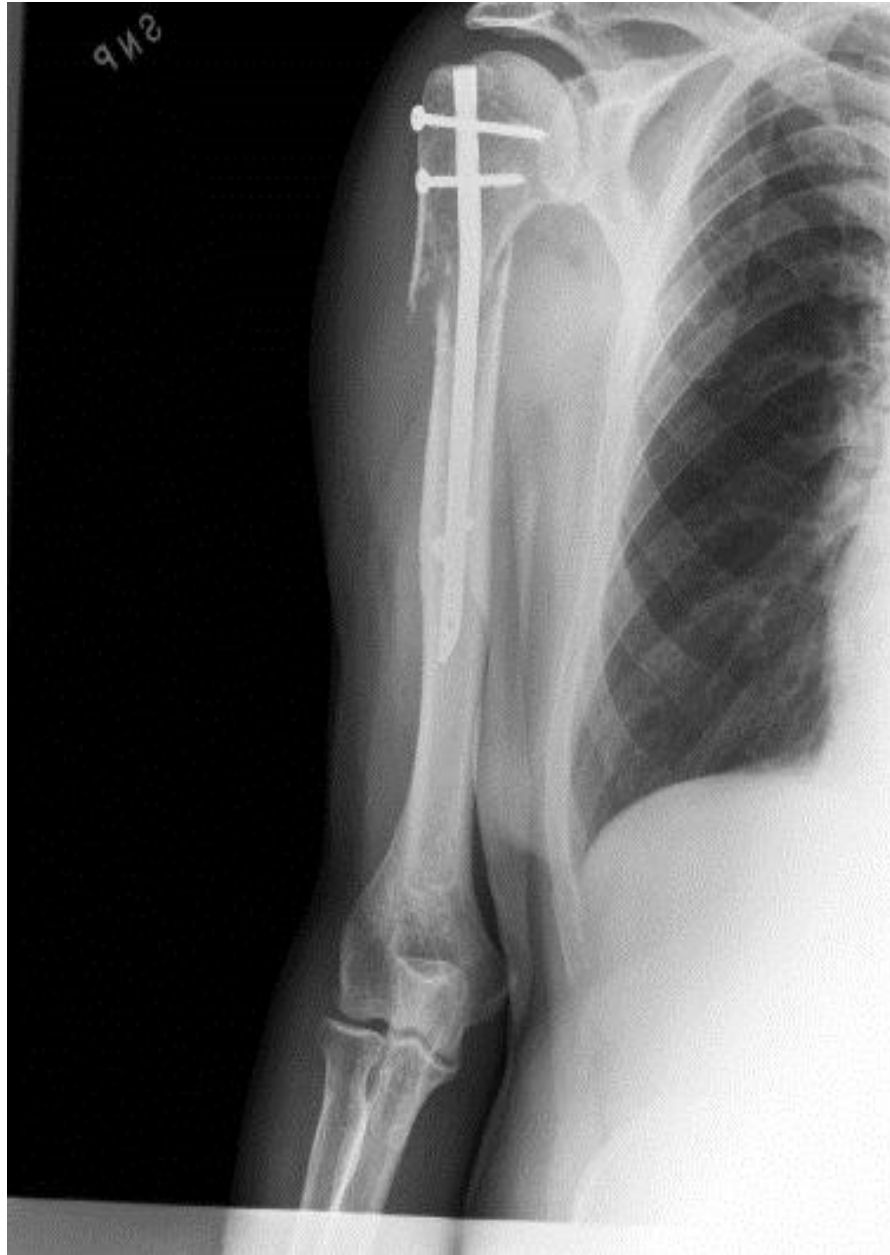MM fract. of humer



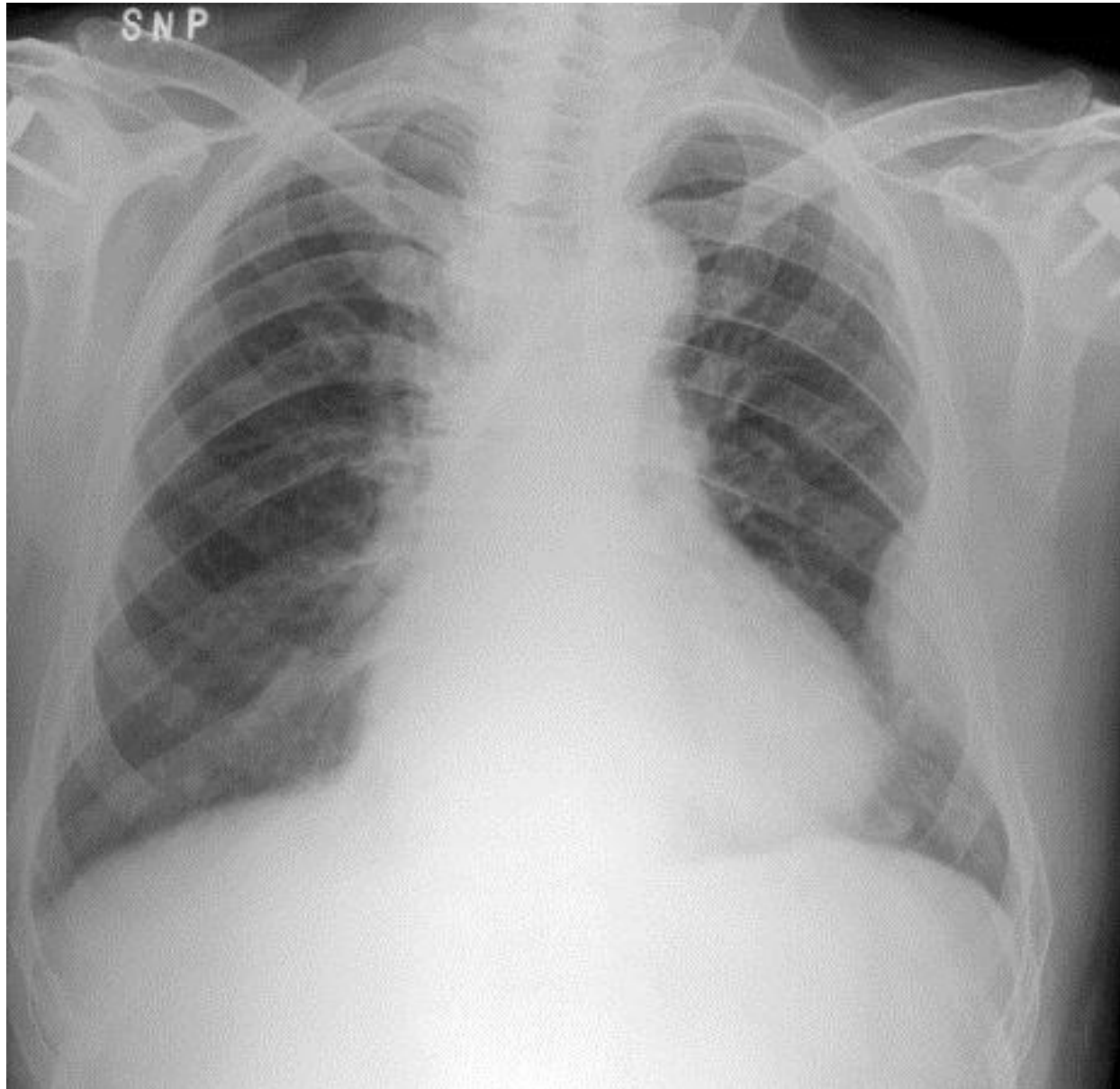
MM



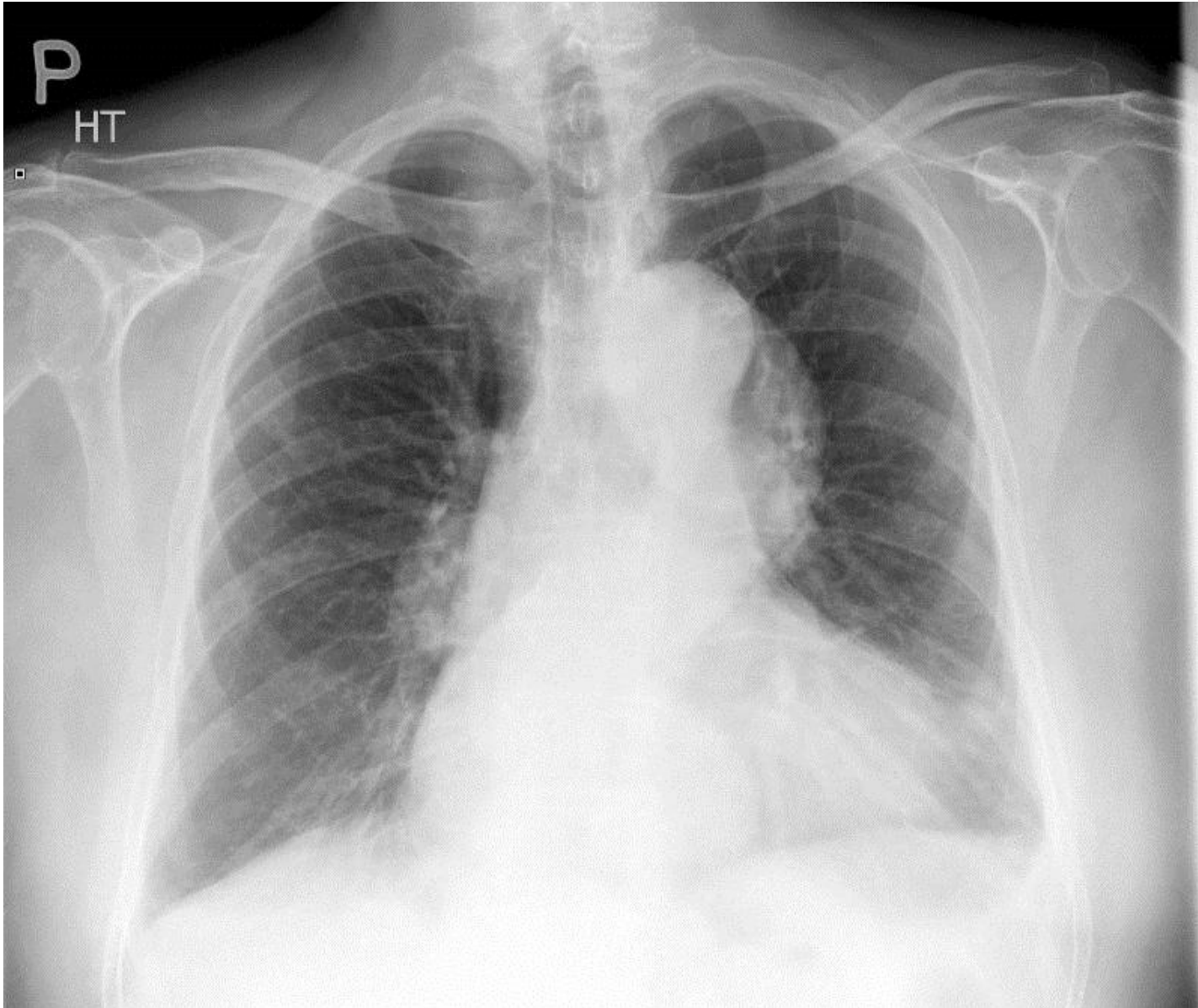
MM



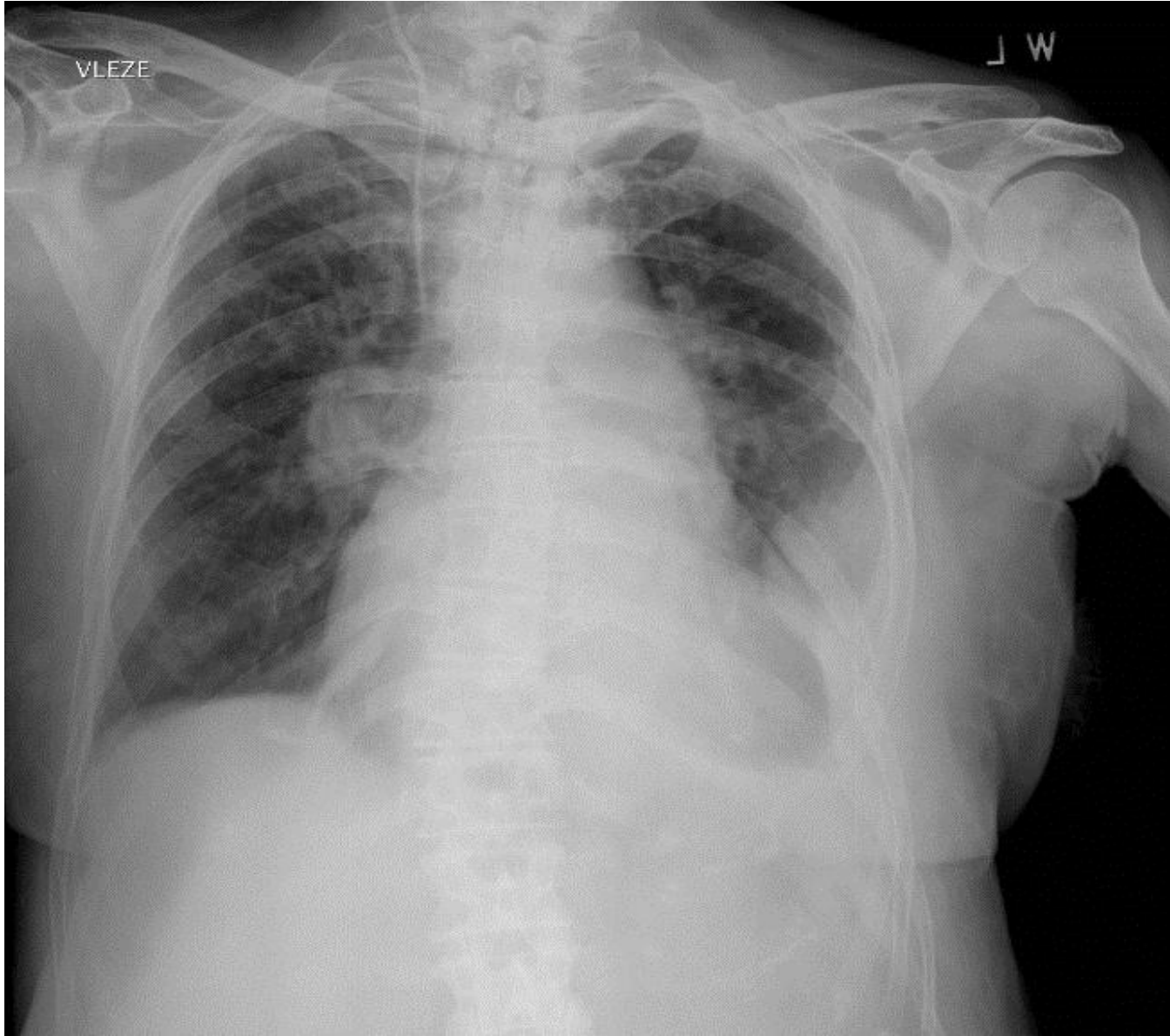
MM



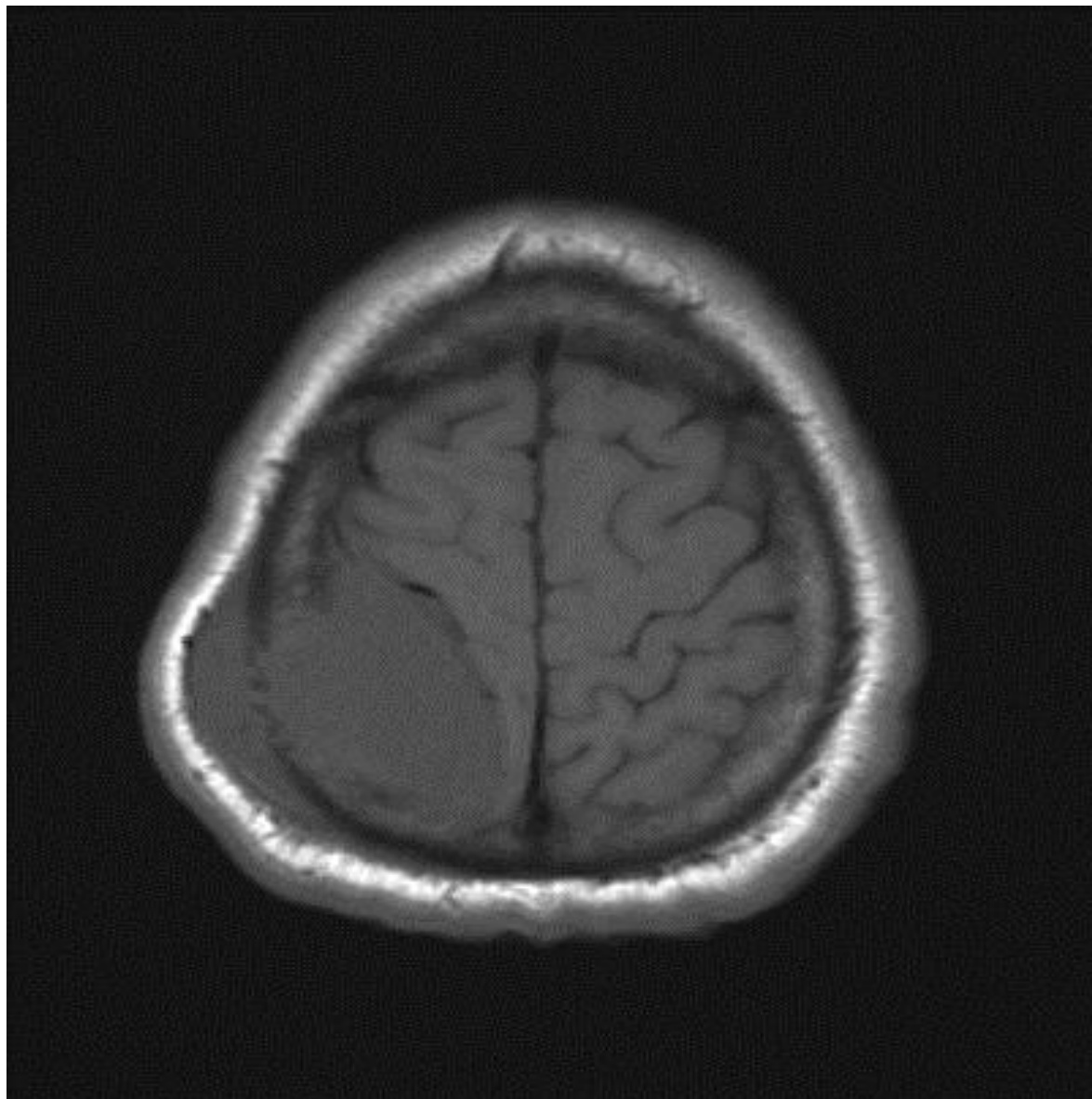
Aneurysma of aorta



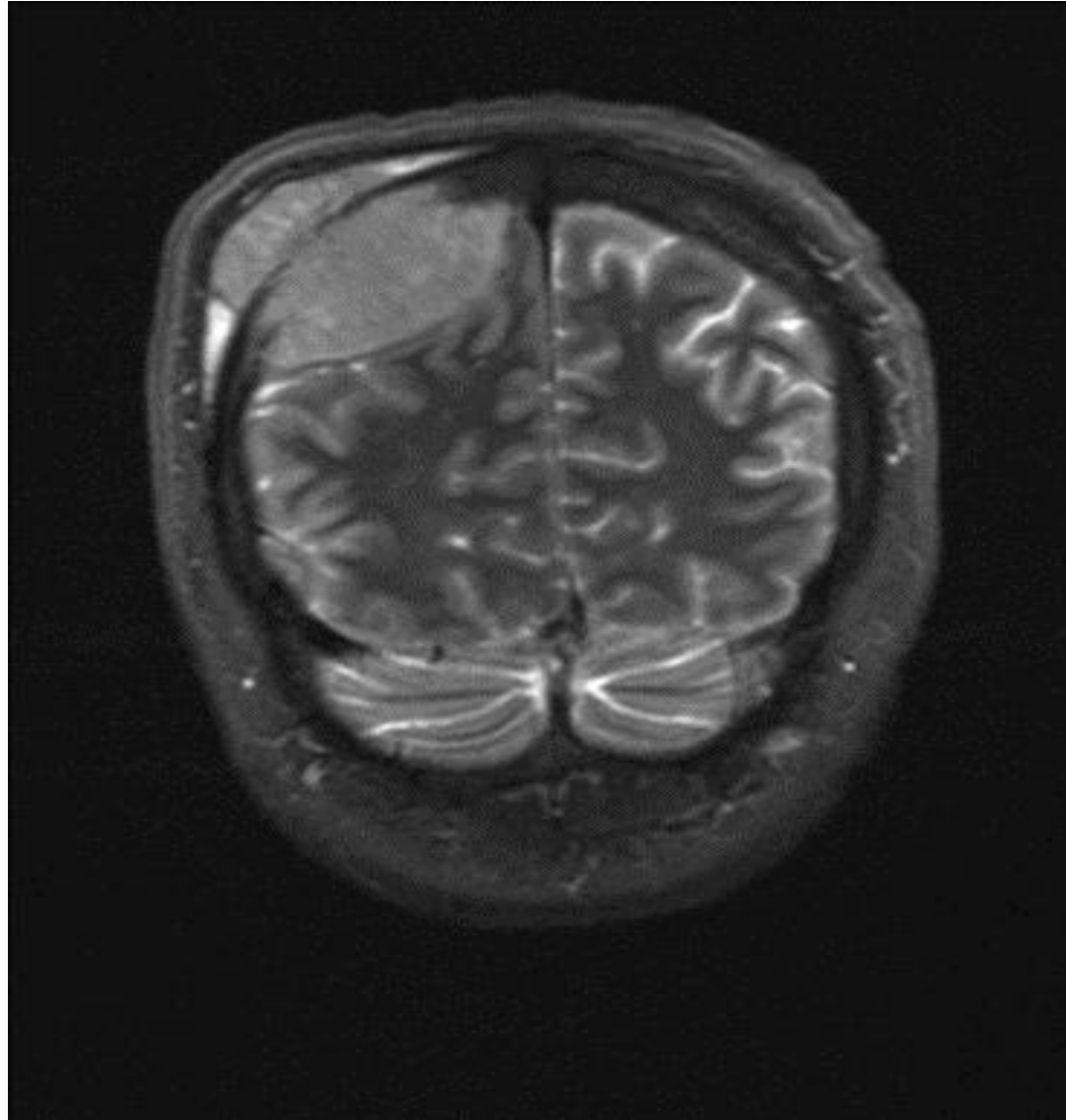
MM fract. of left clavicle
and tumor mass of left chest wall



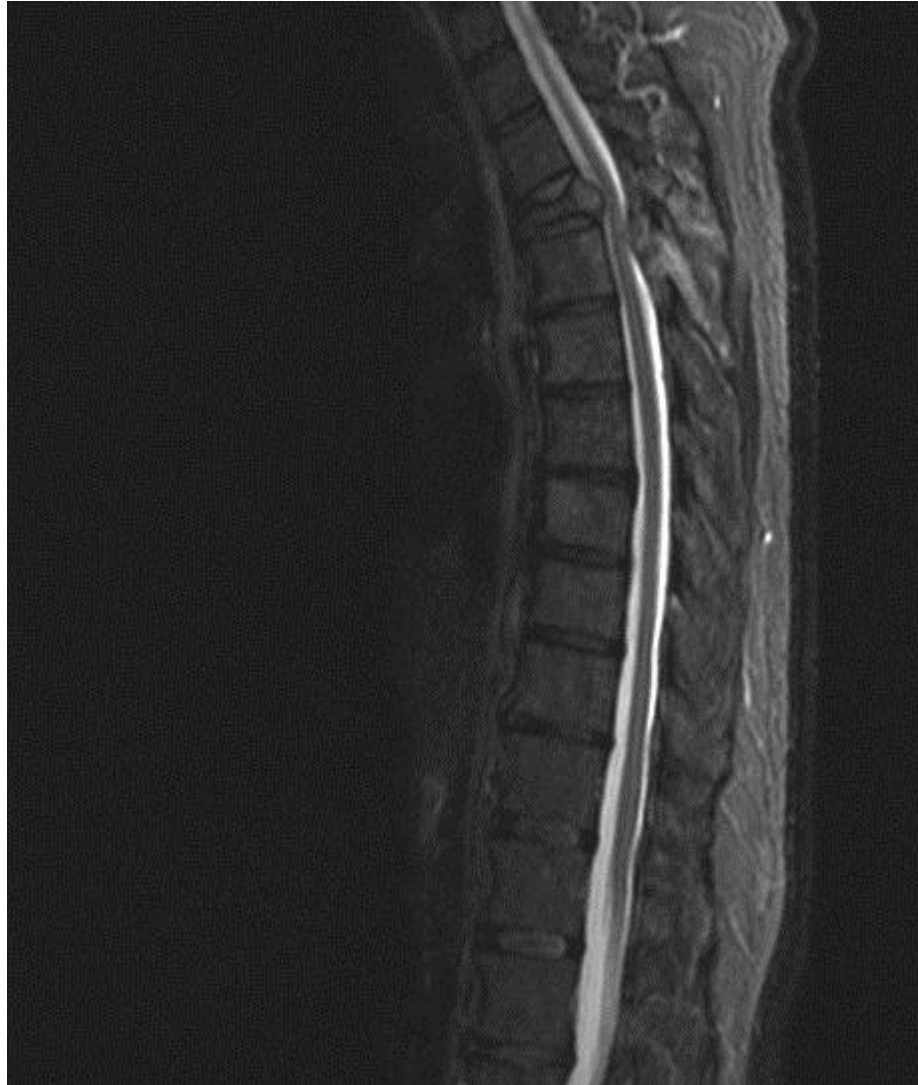MRI – MM (p.B.)



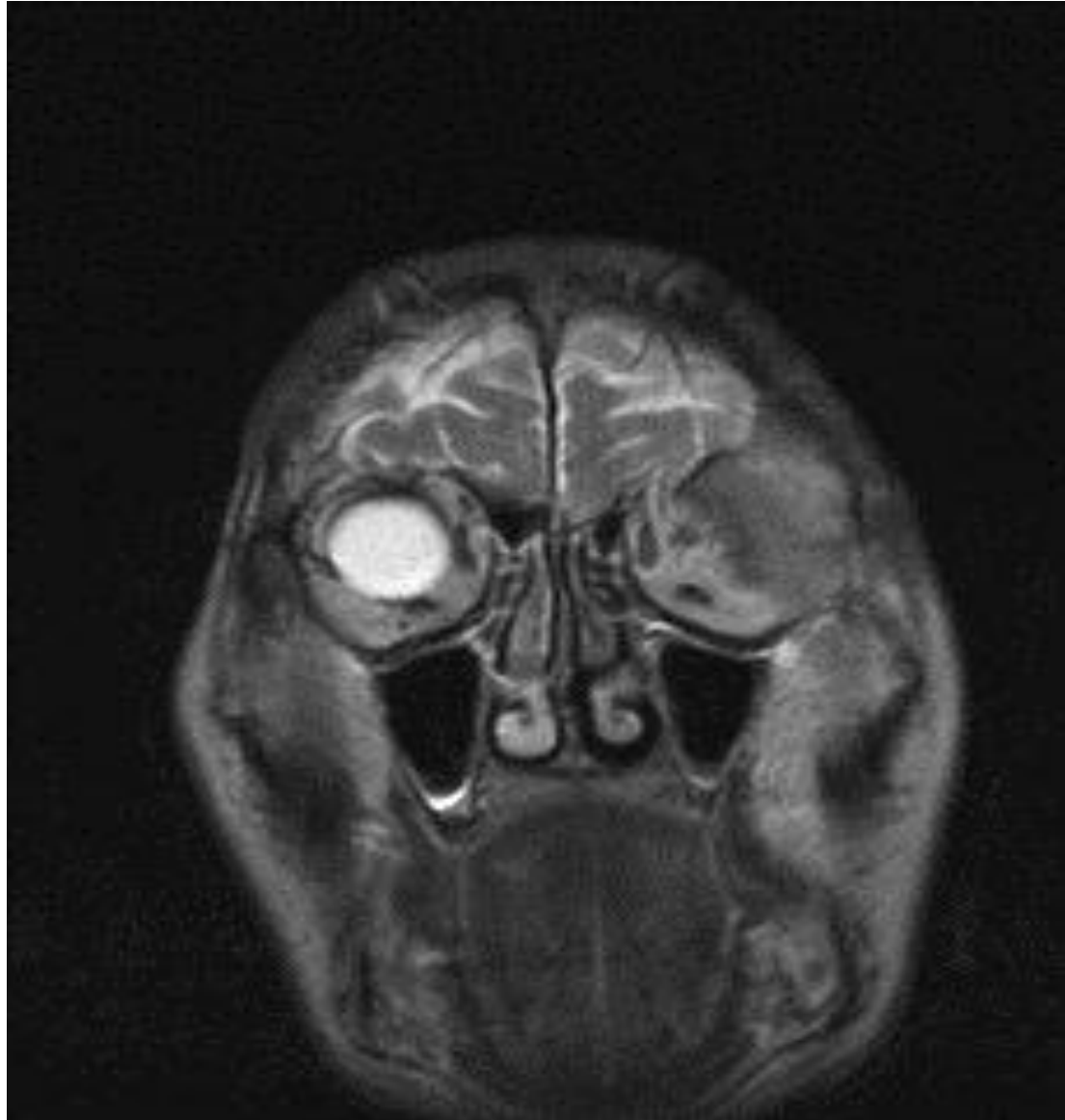MRI – MM (p.B)



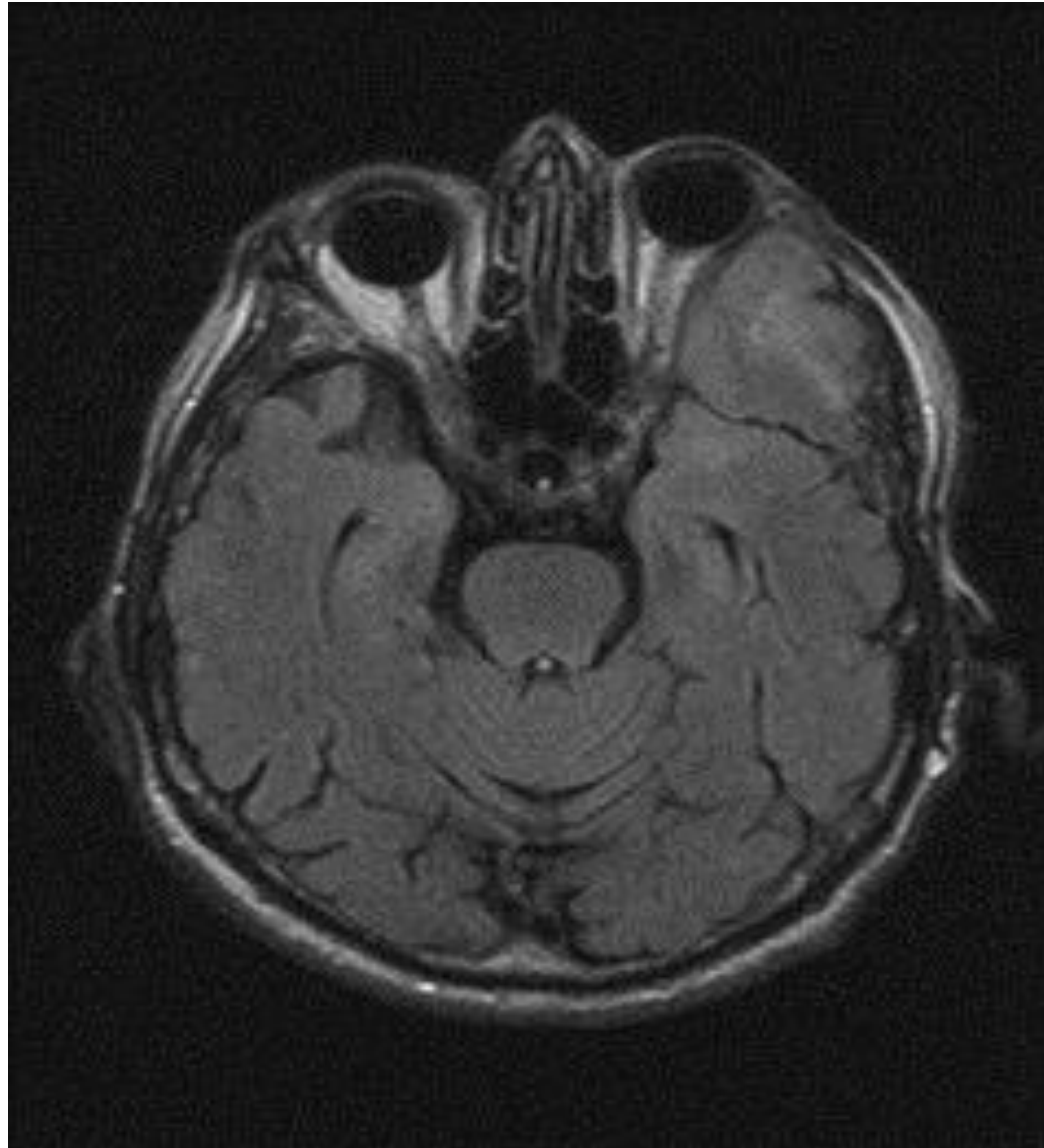
MRI -stenosis



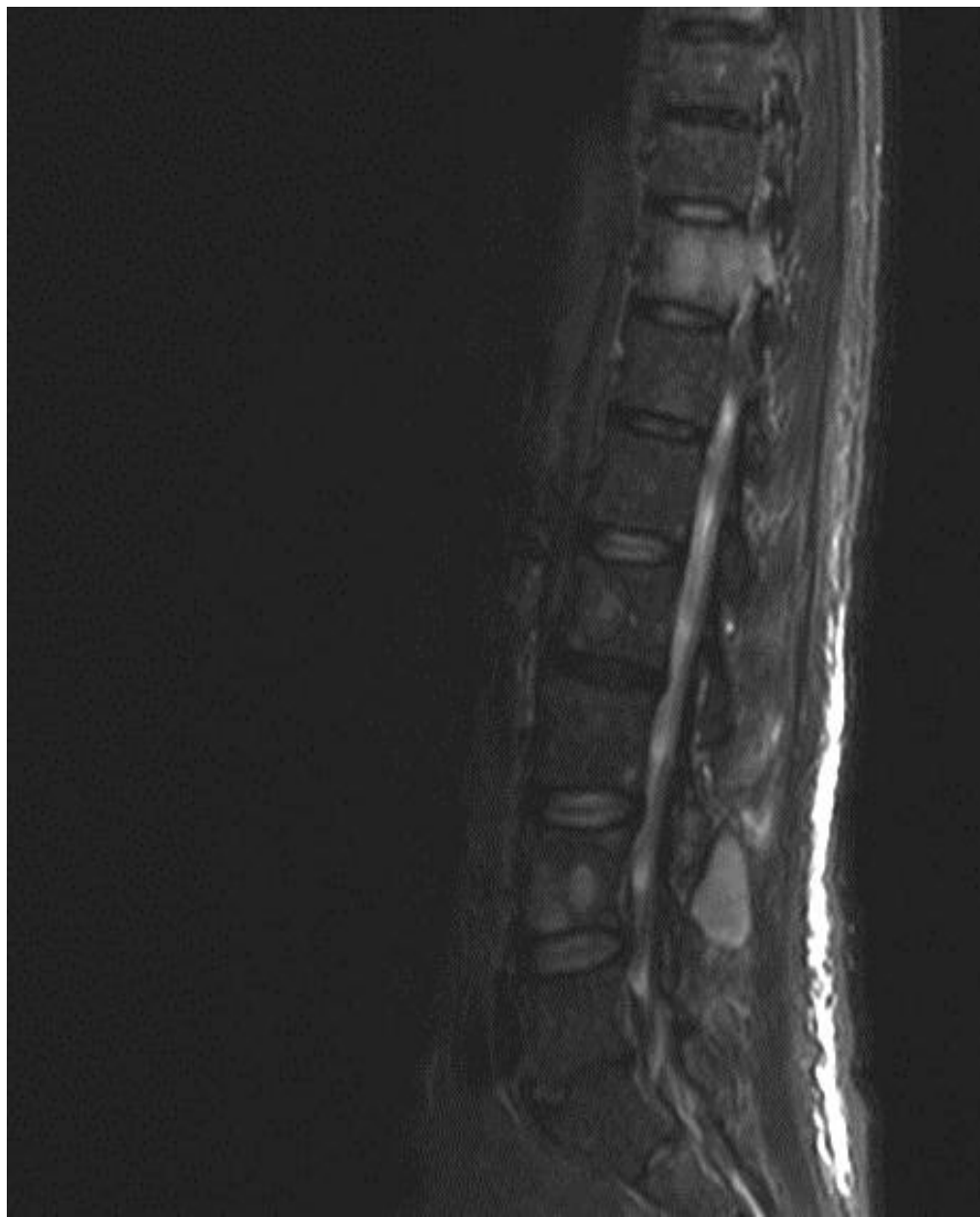
MRI (p.K)



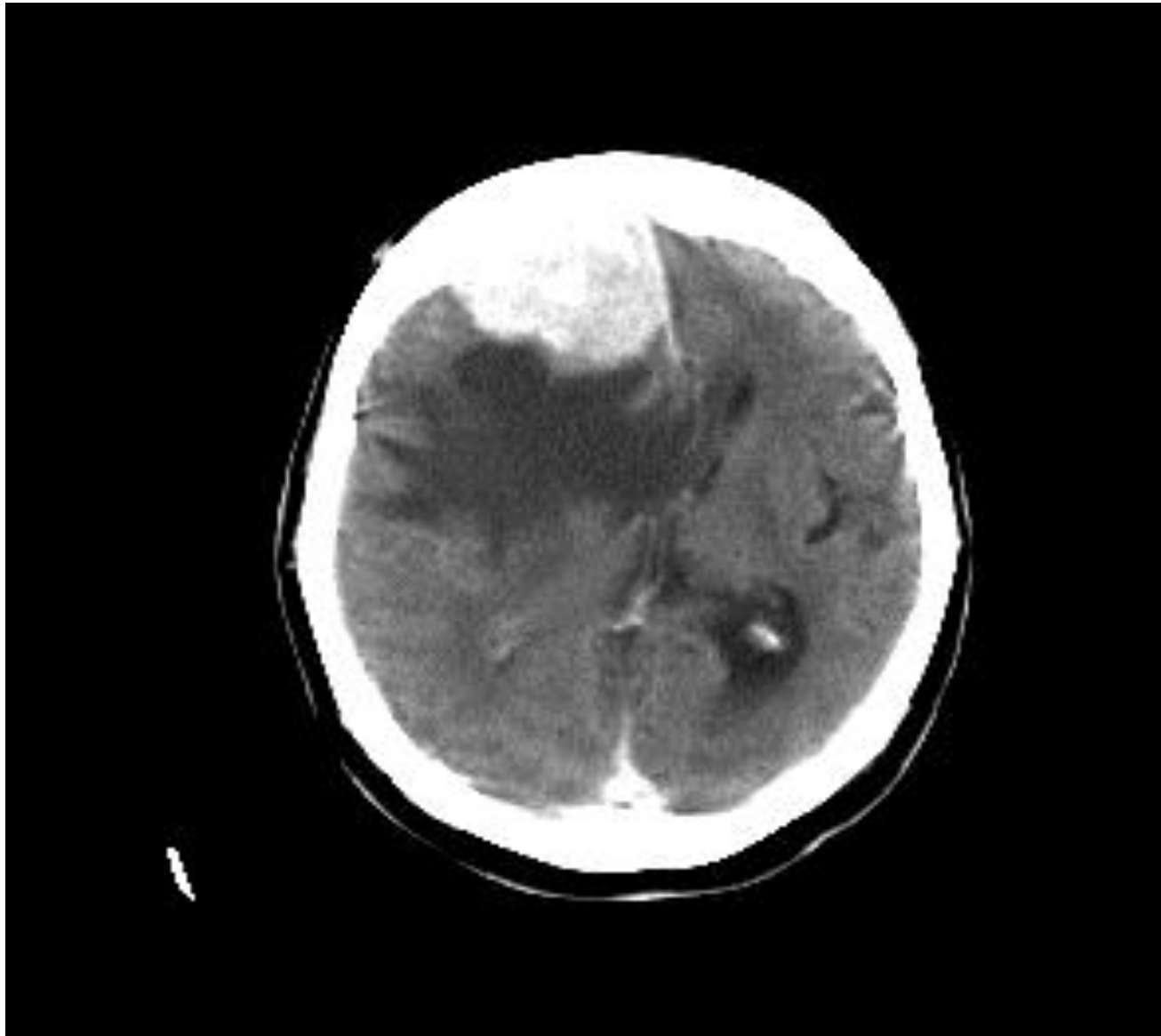
MRI (p.K)



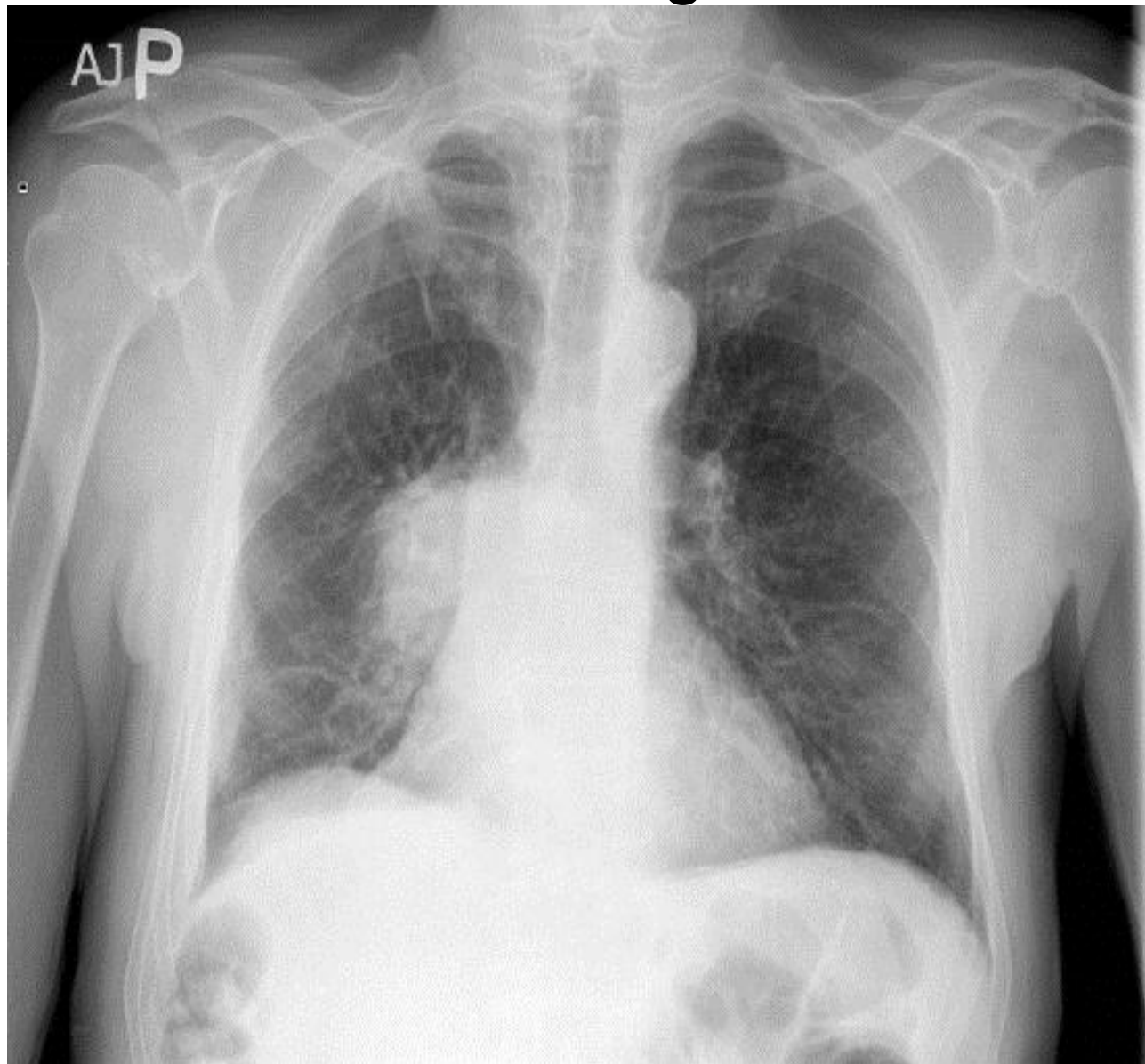
MM compr.of spine



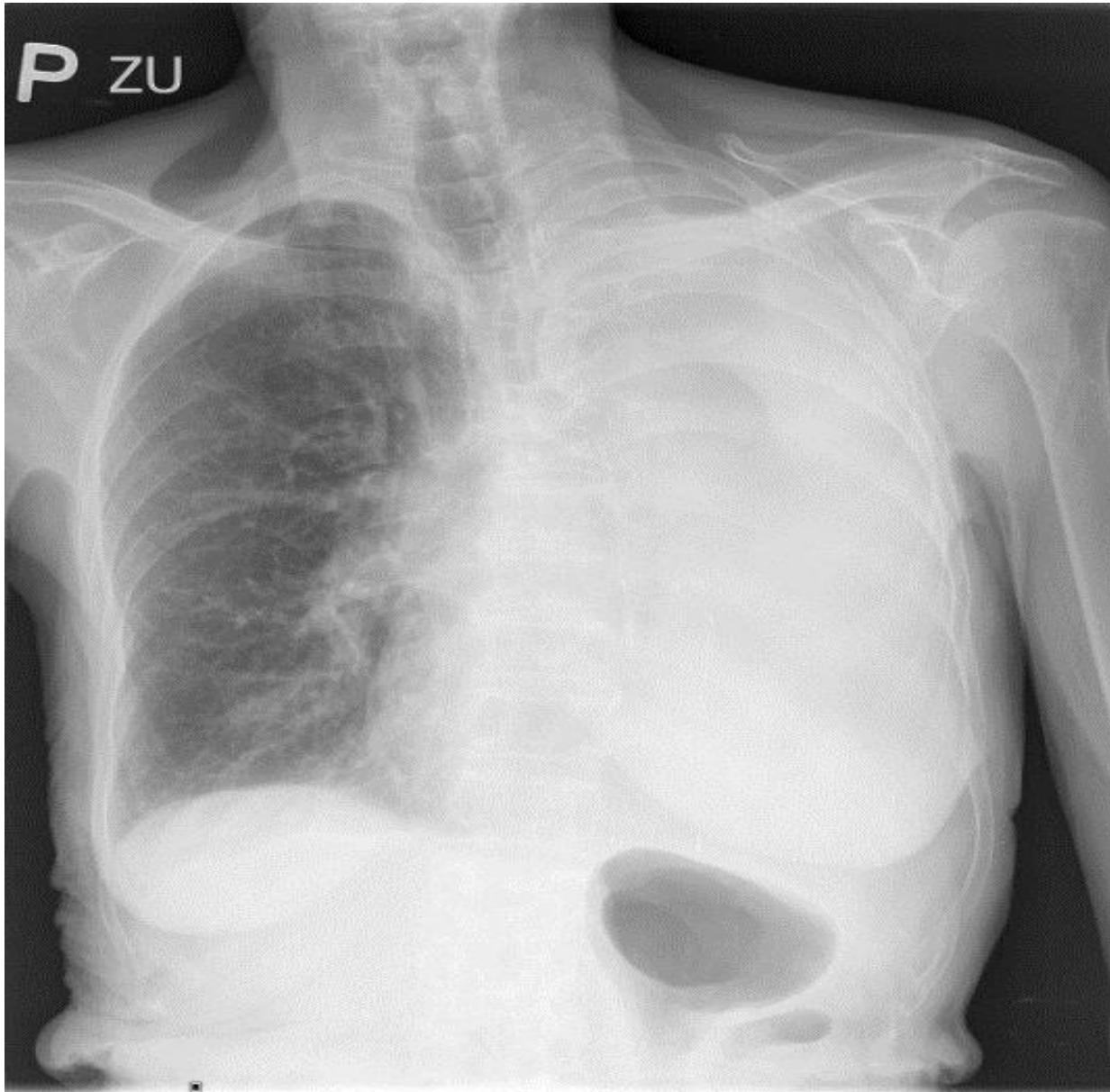
Meningeoma in patient with MM



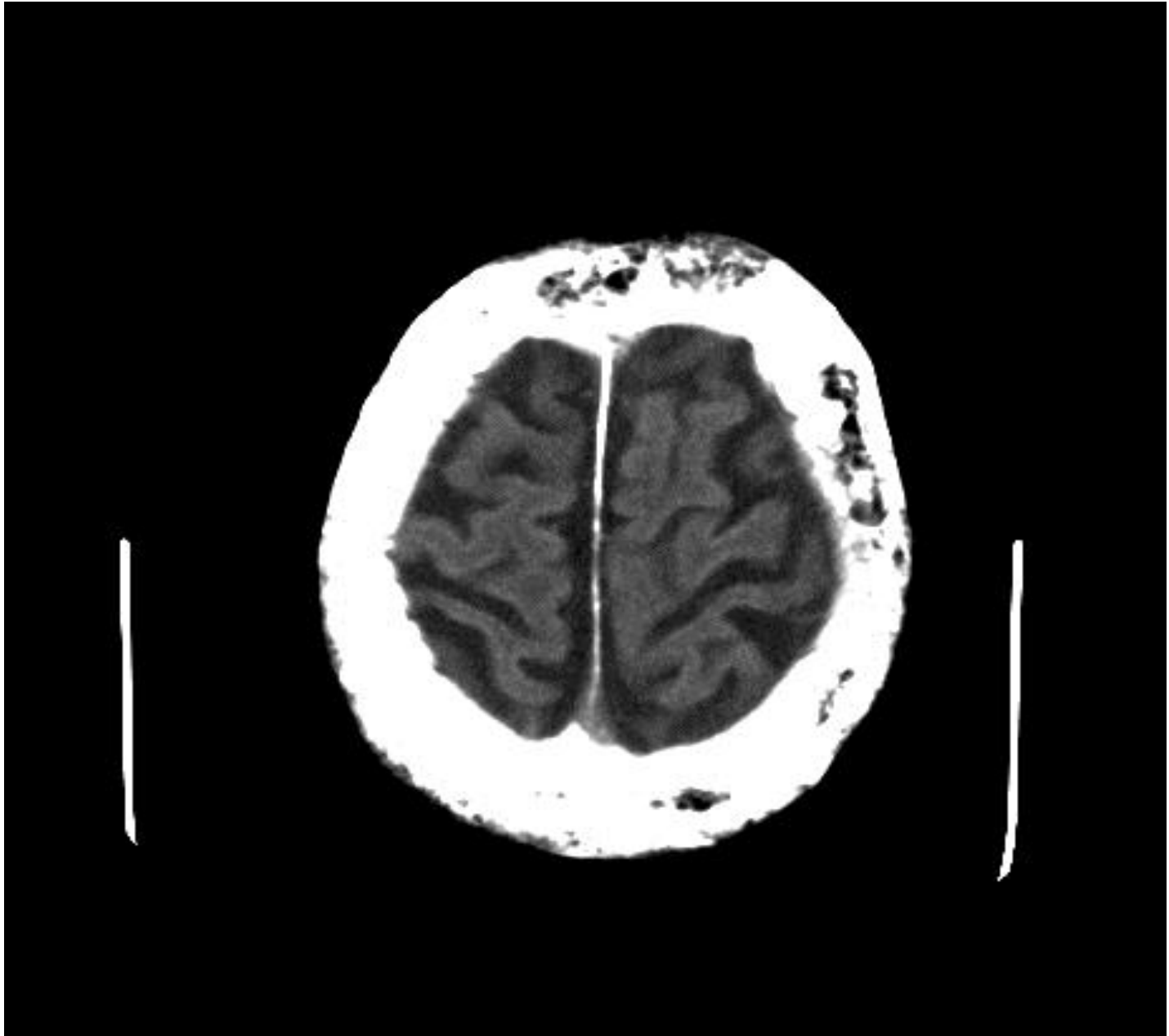
Ca of lung



Atelectasis of left lobe



CT - Paget disease



XRAY -m.Paget



