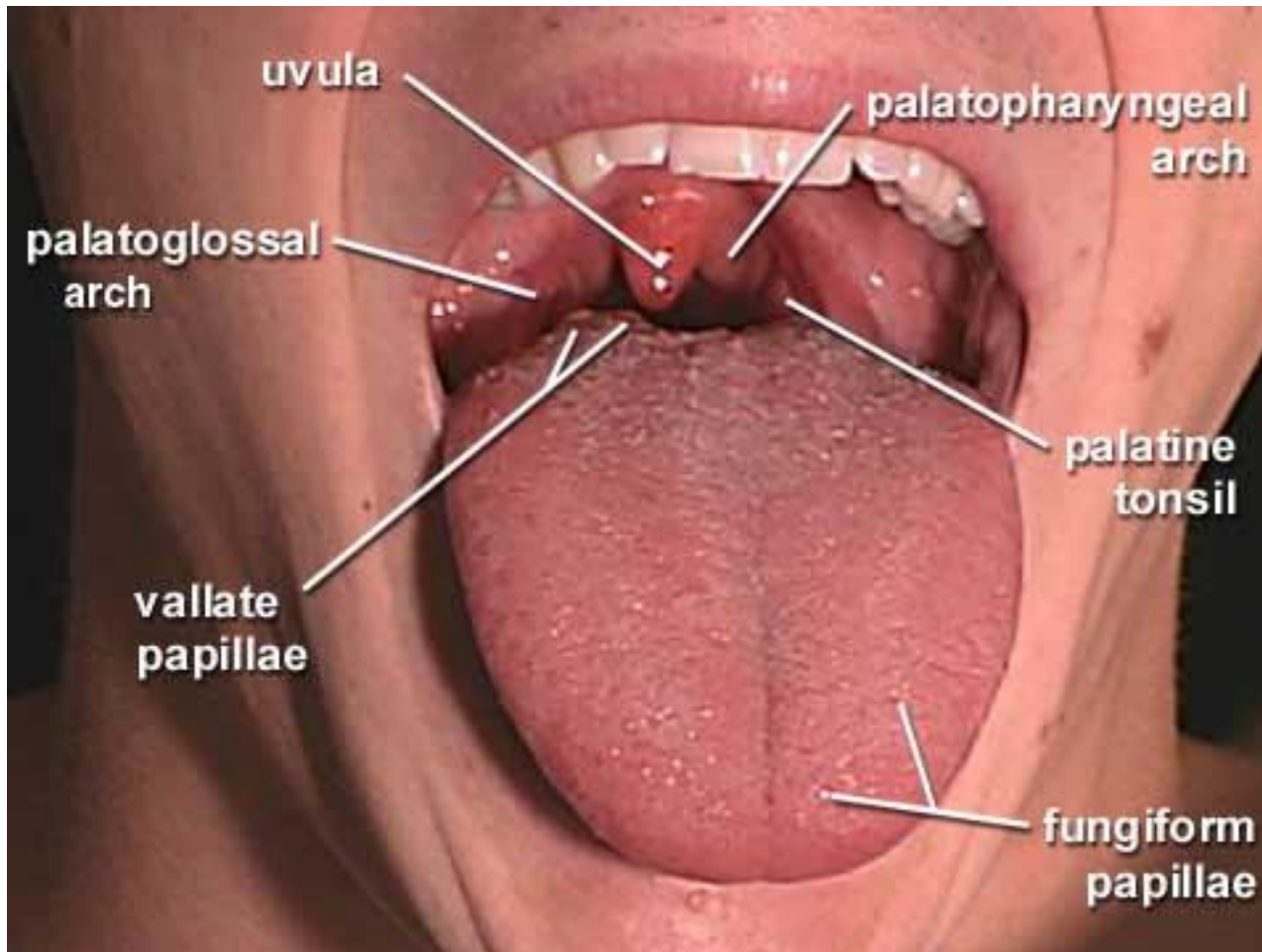
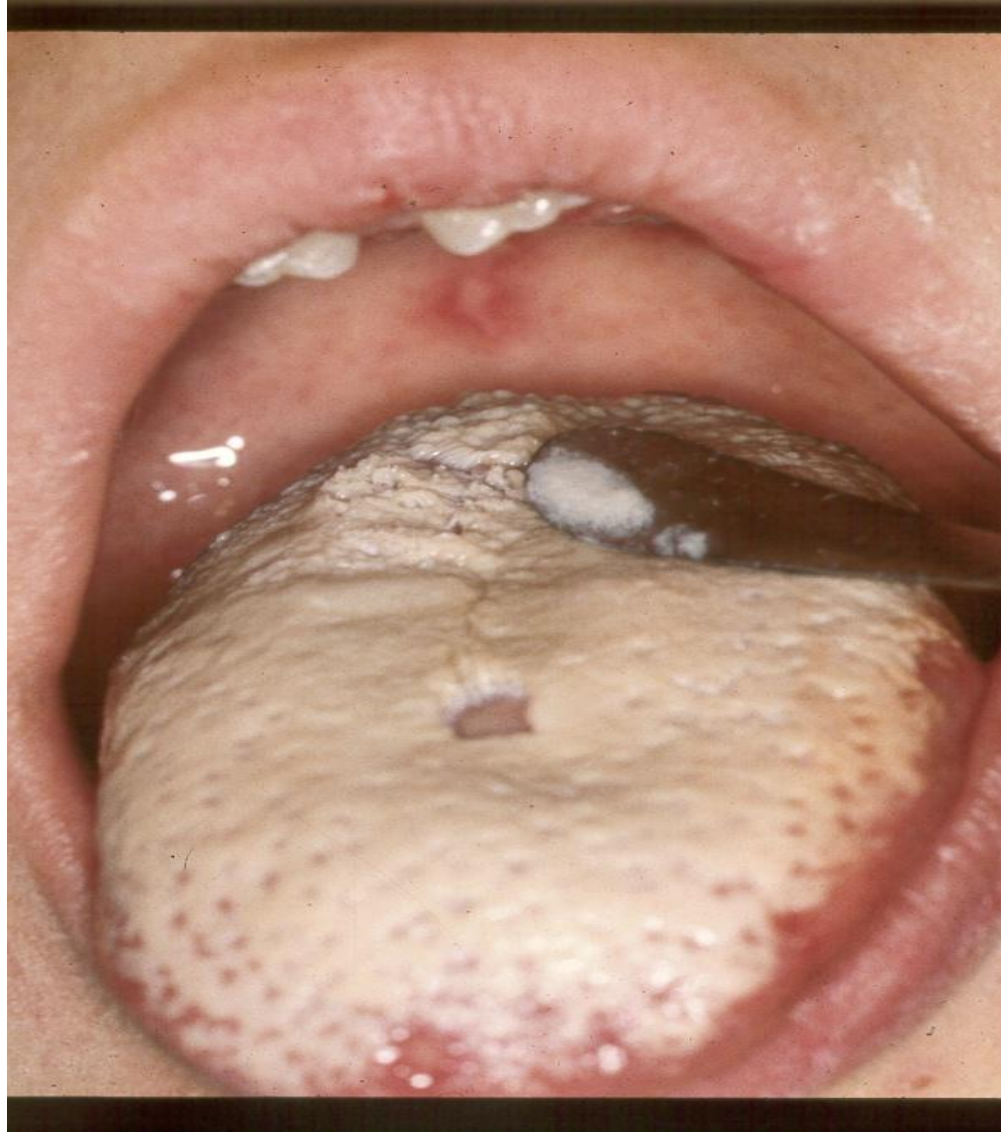

Nálezky v dutině ústní

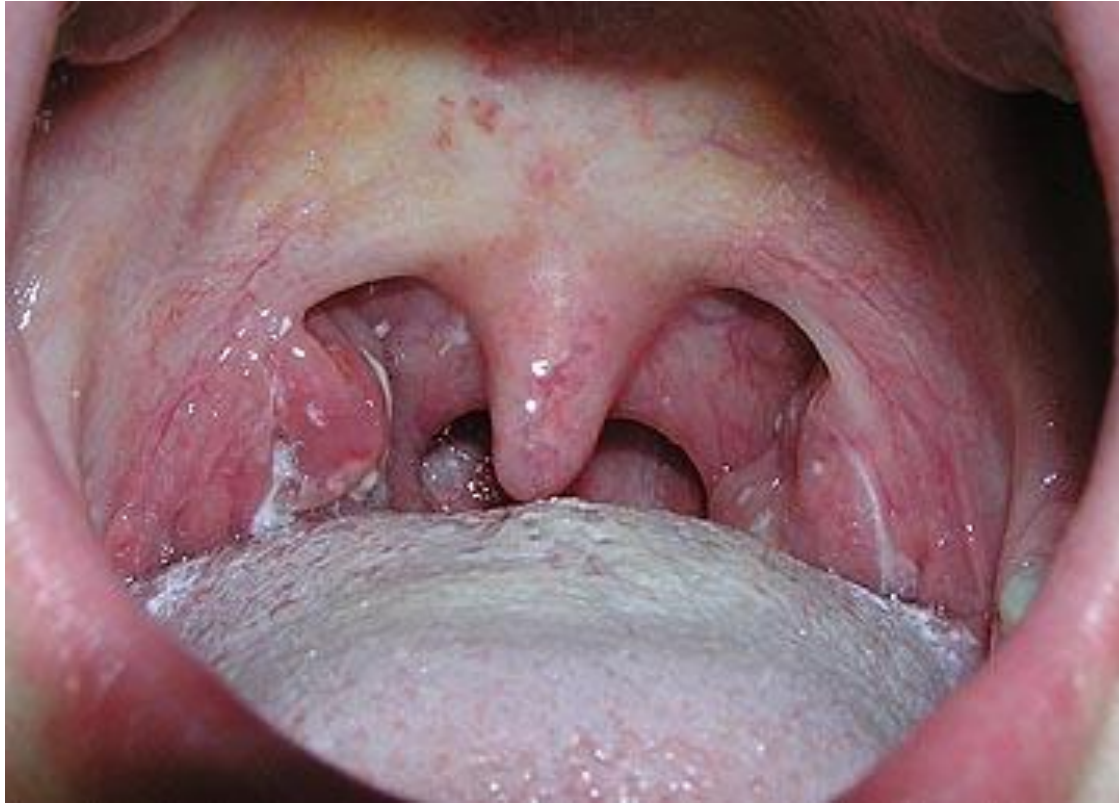Dutina ústní



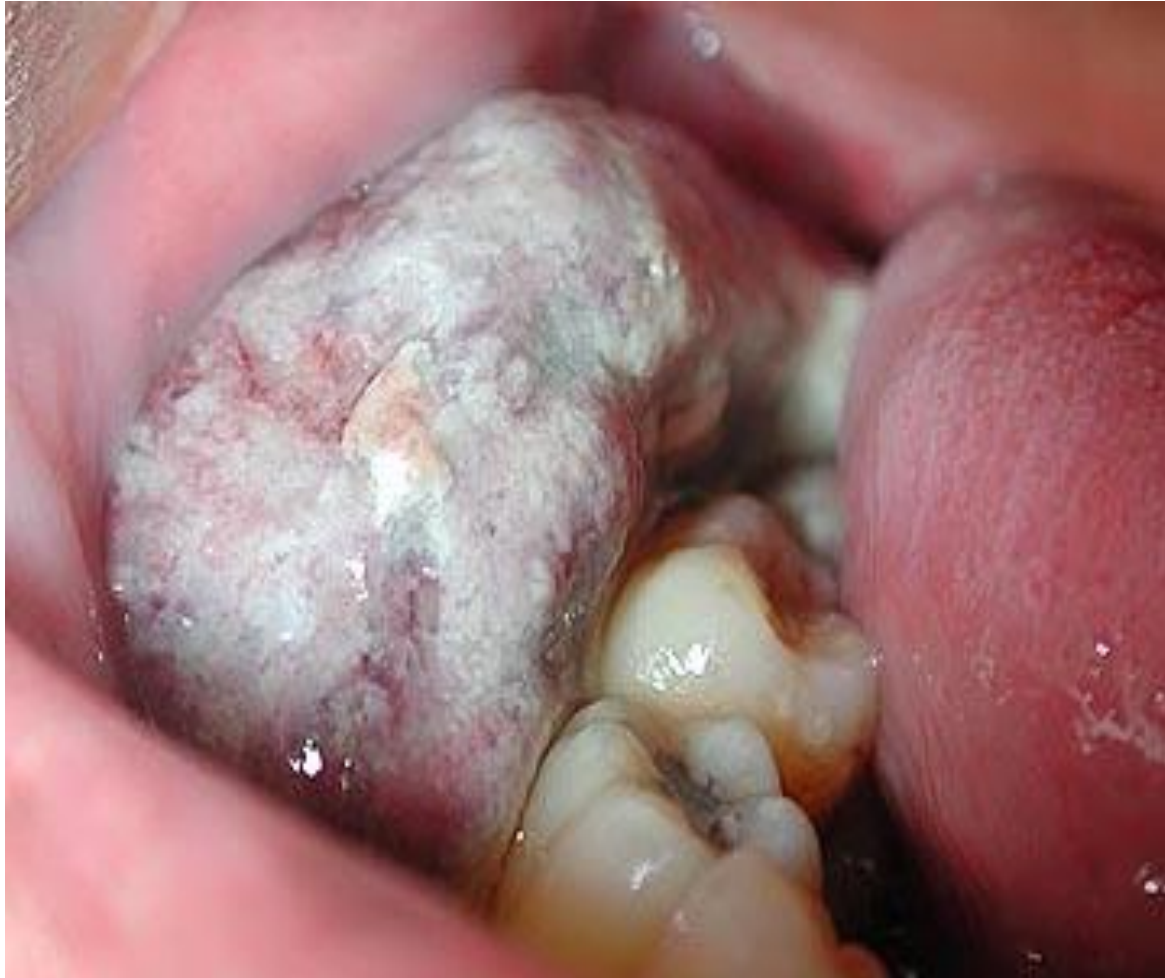candidiasis



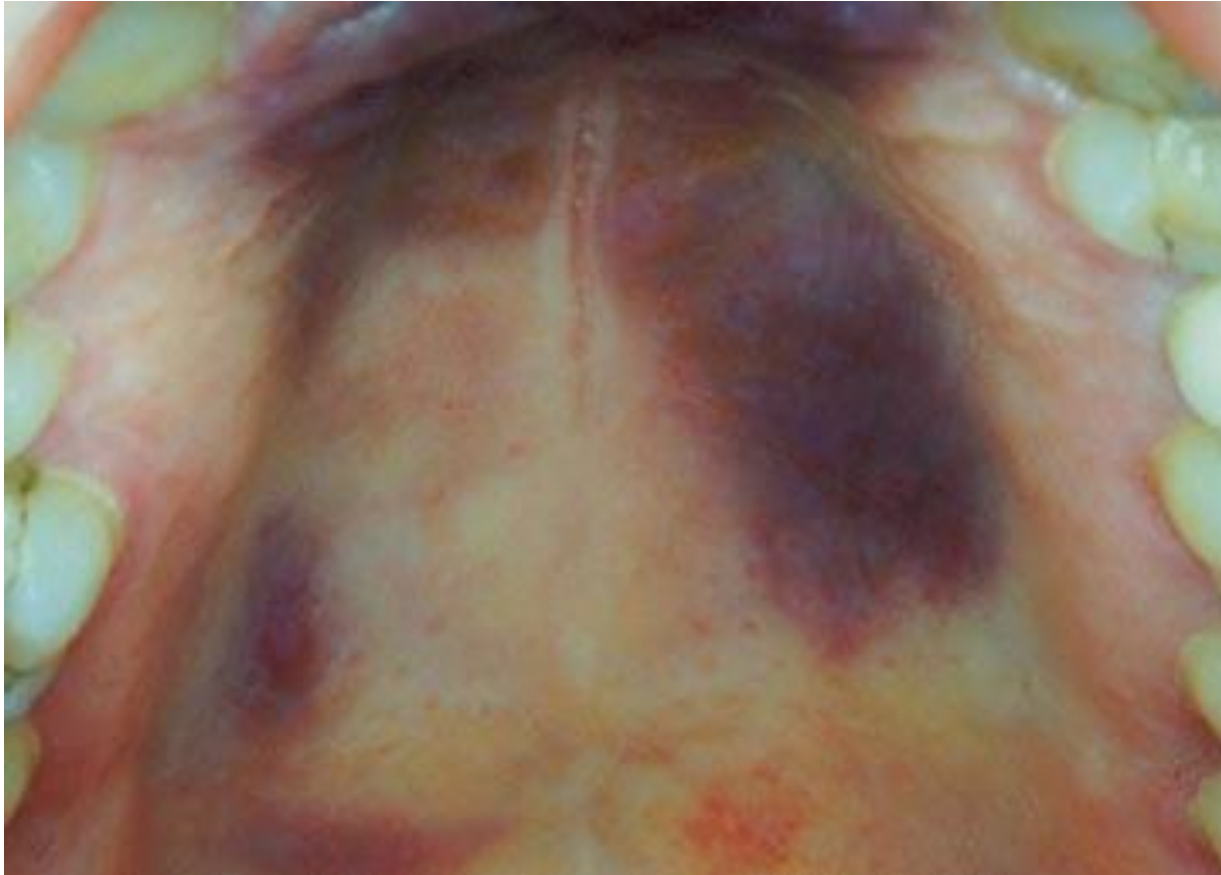
mononukleoza



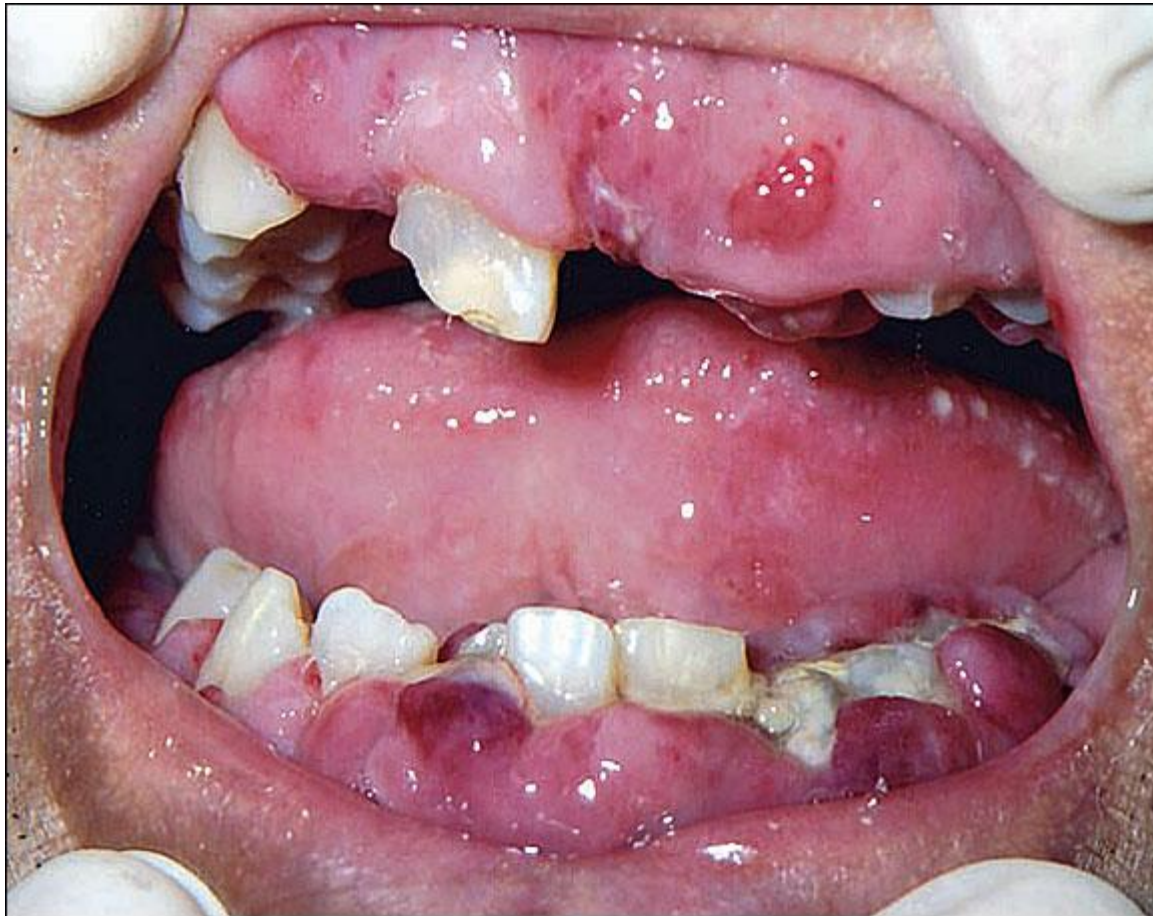Burkitův lymfom, HIV ,



Kaposiho sarkom

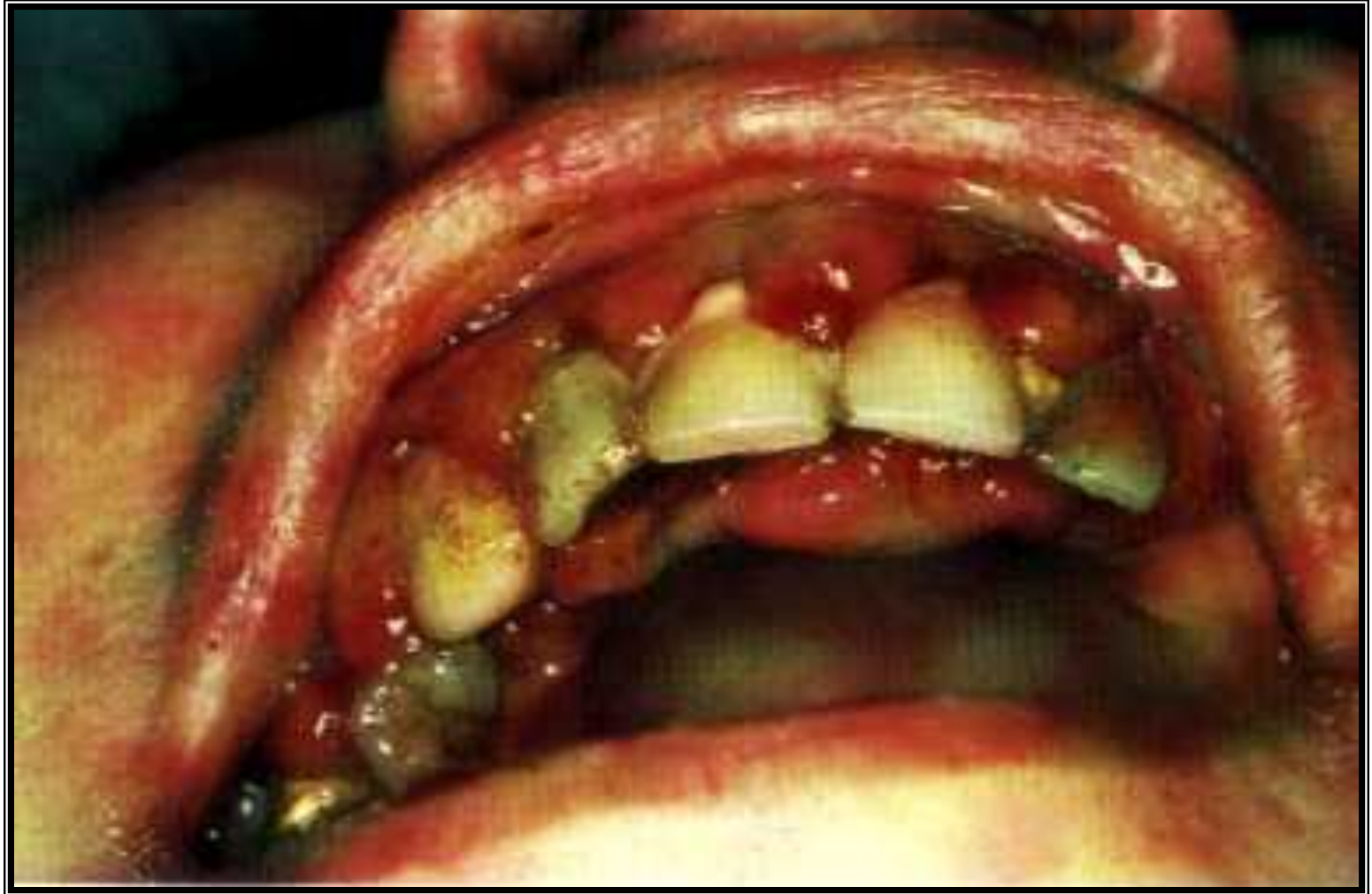

leukemie

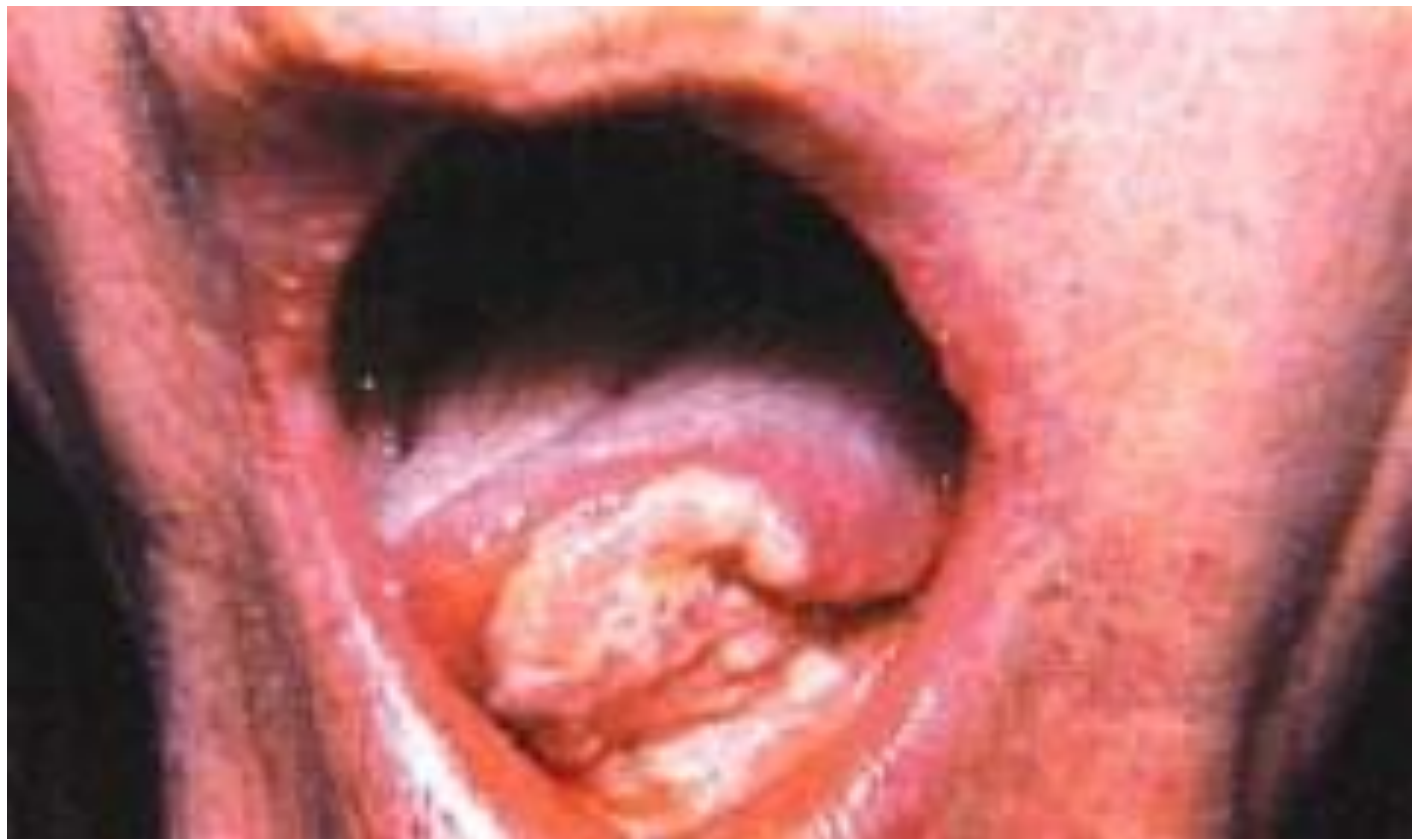

Figure—Prominent gingival hypertrophy.

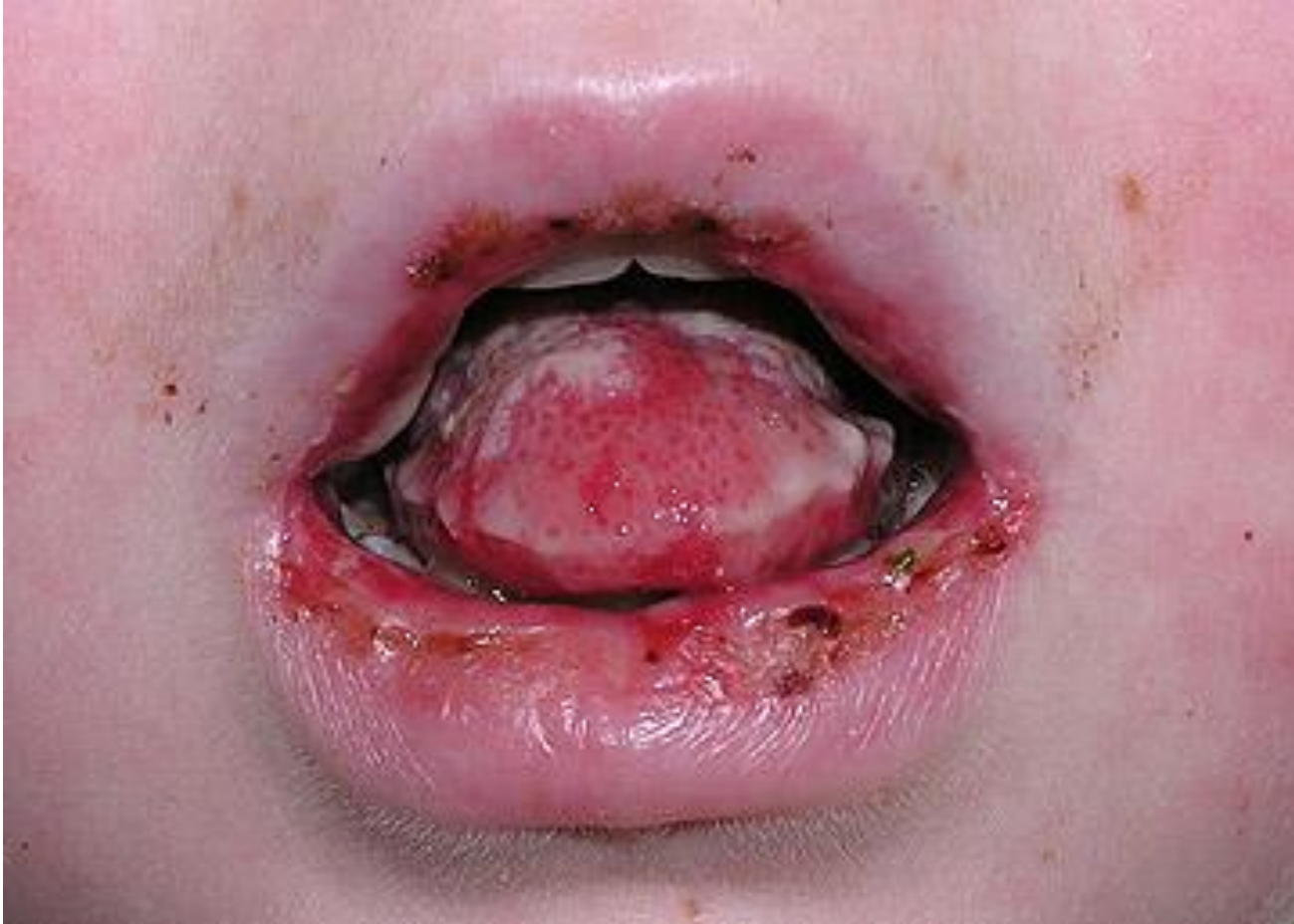AML-M5 - Gum Hypertrophy:



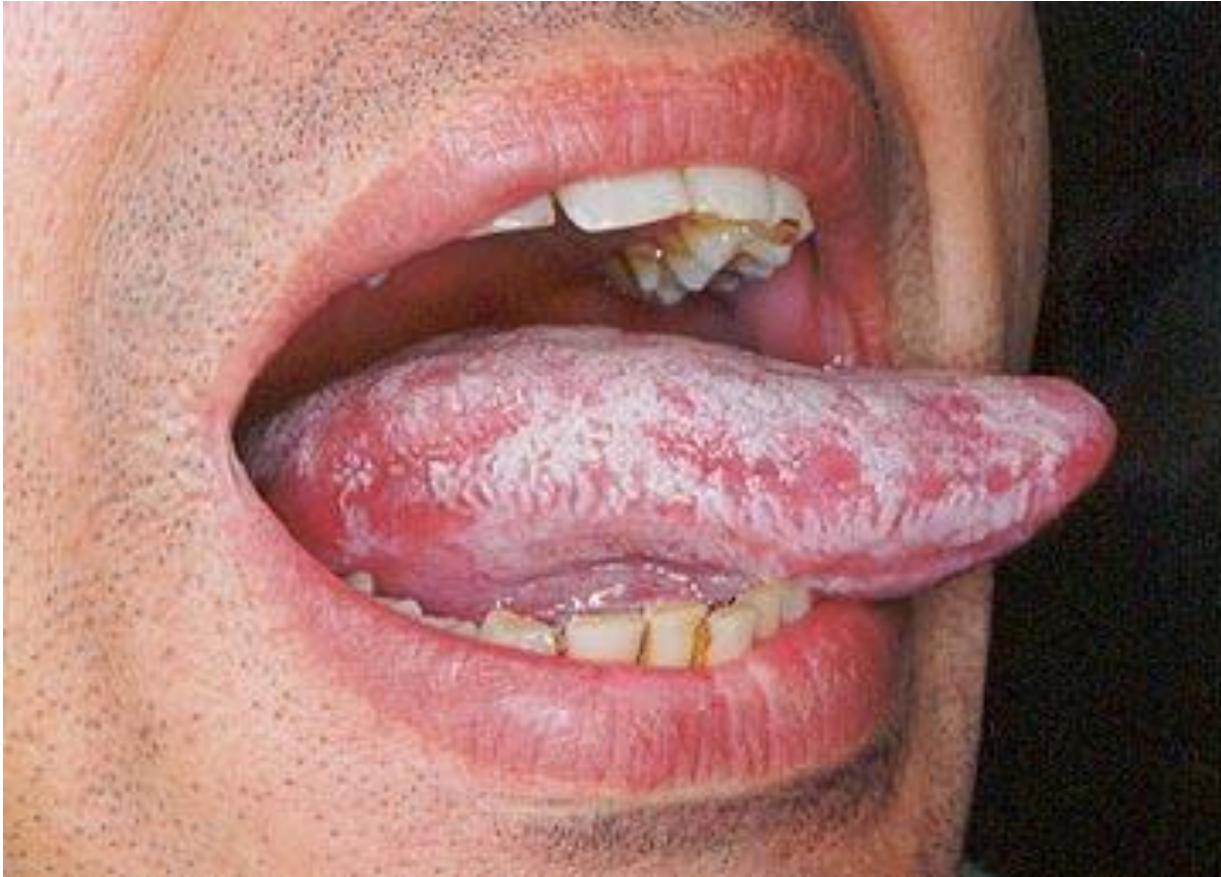Ca jazyka



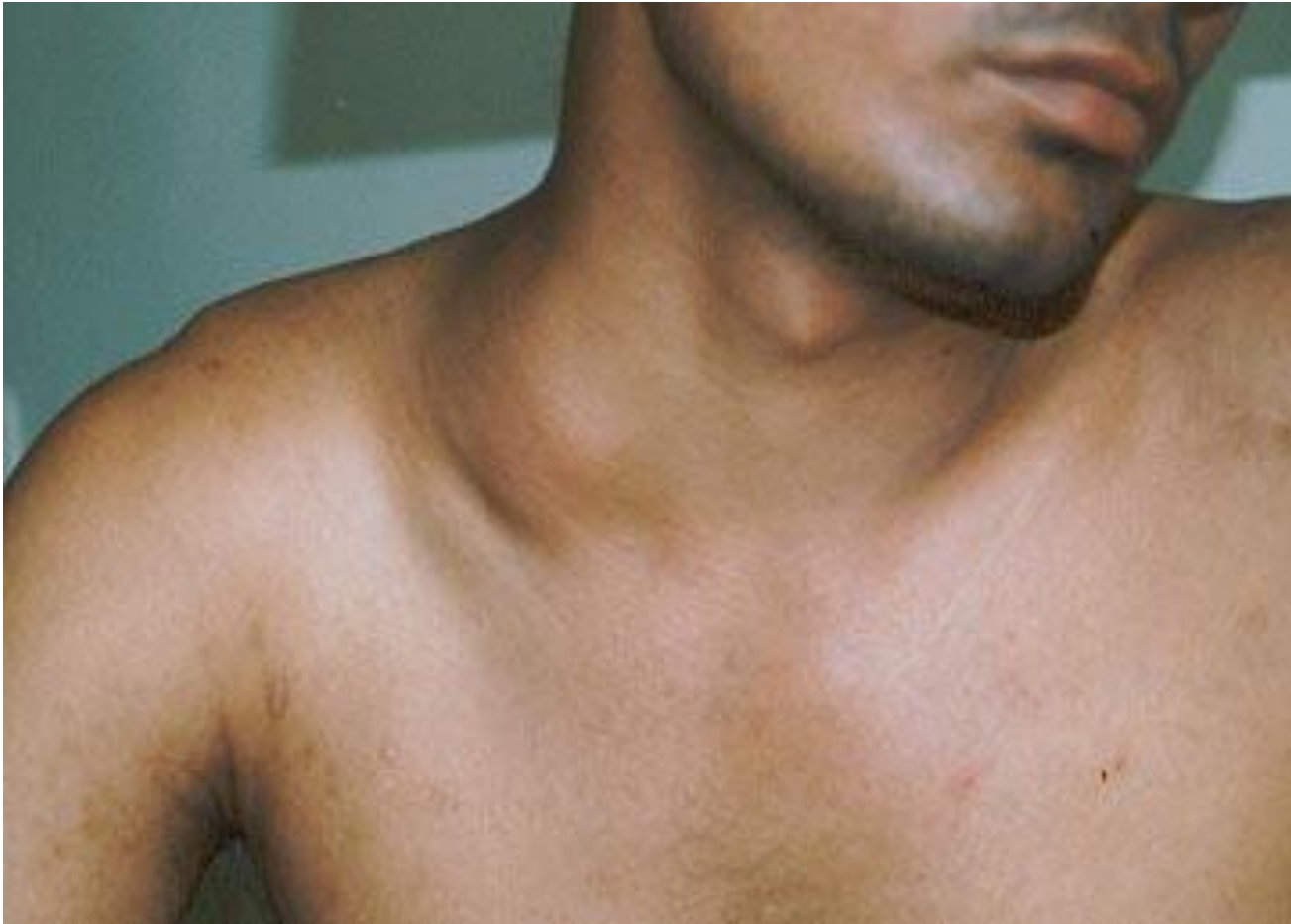Gingivitis herpetica



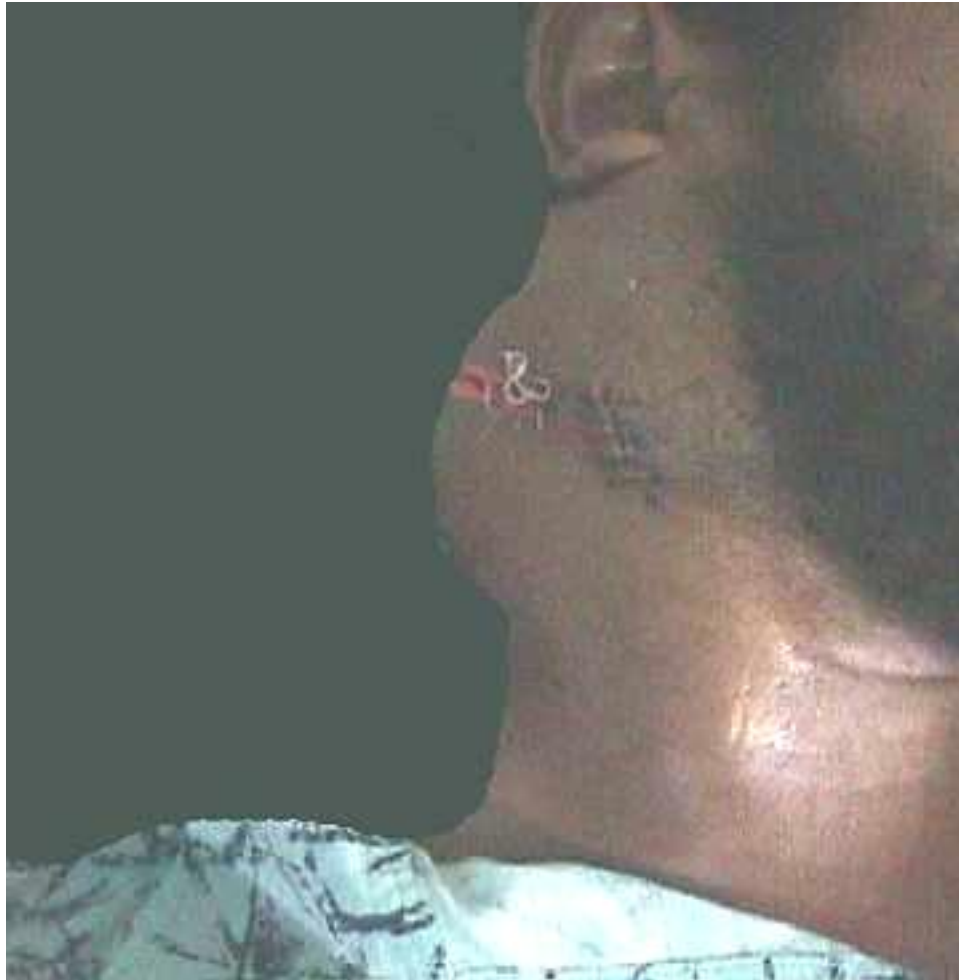leukoplakie



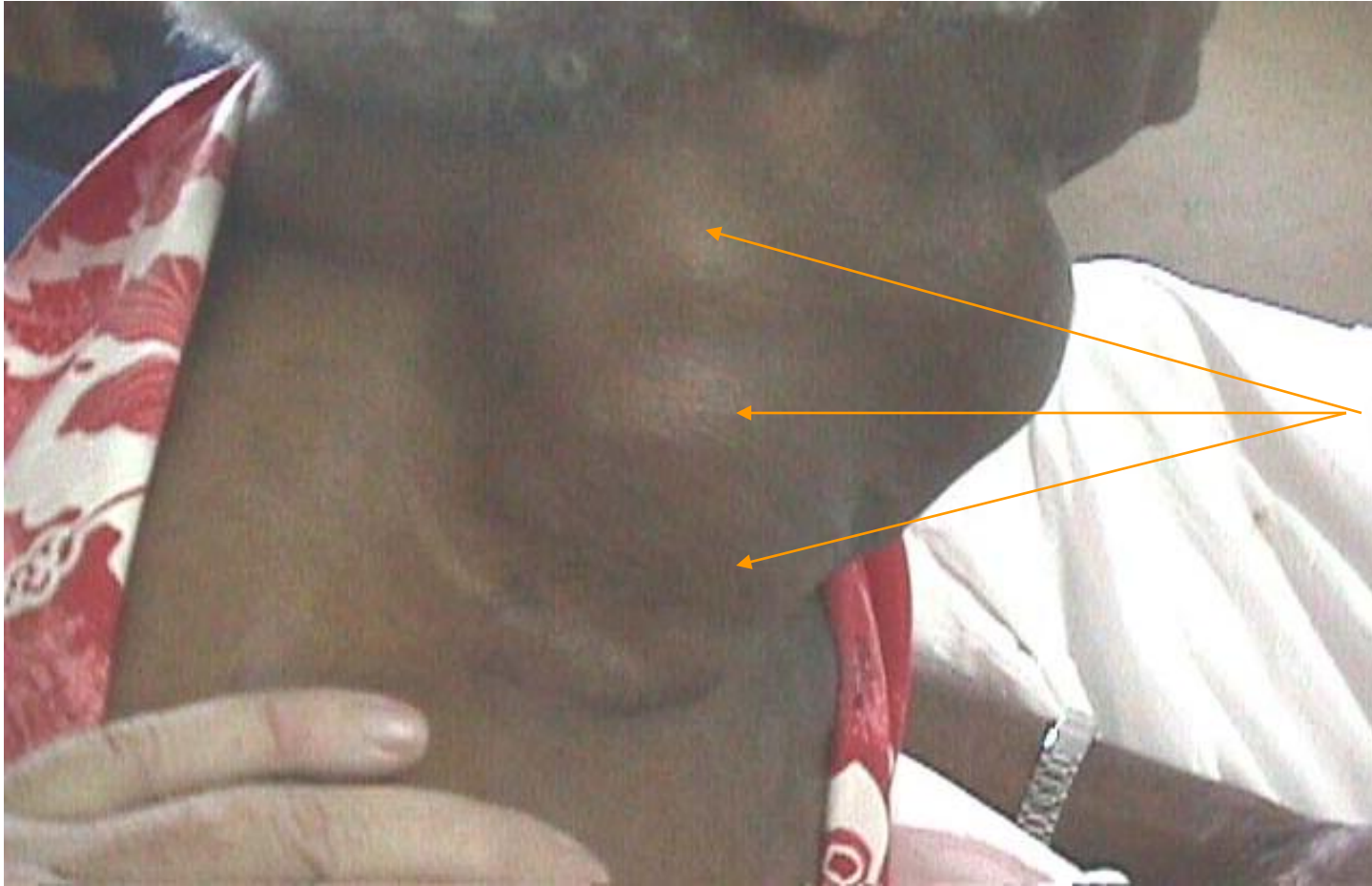Tbc lymadenopatie



Right neck mass

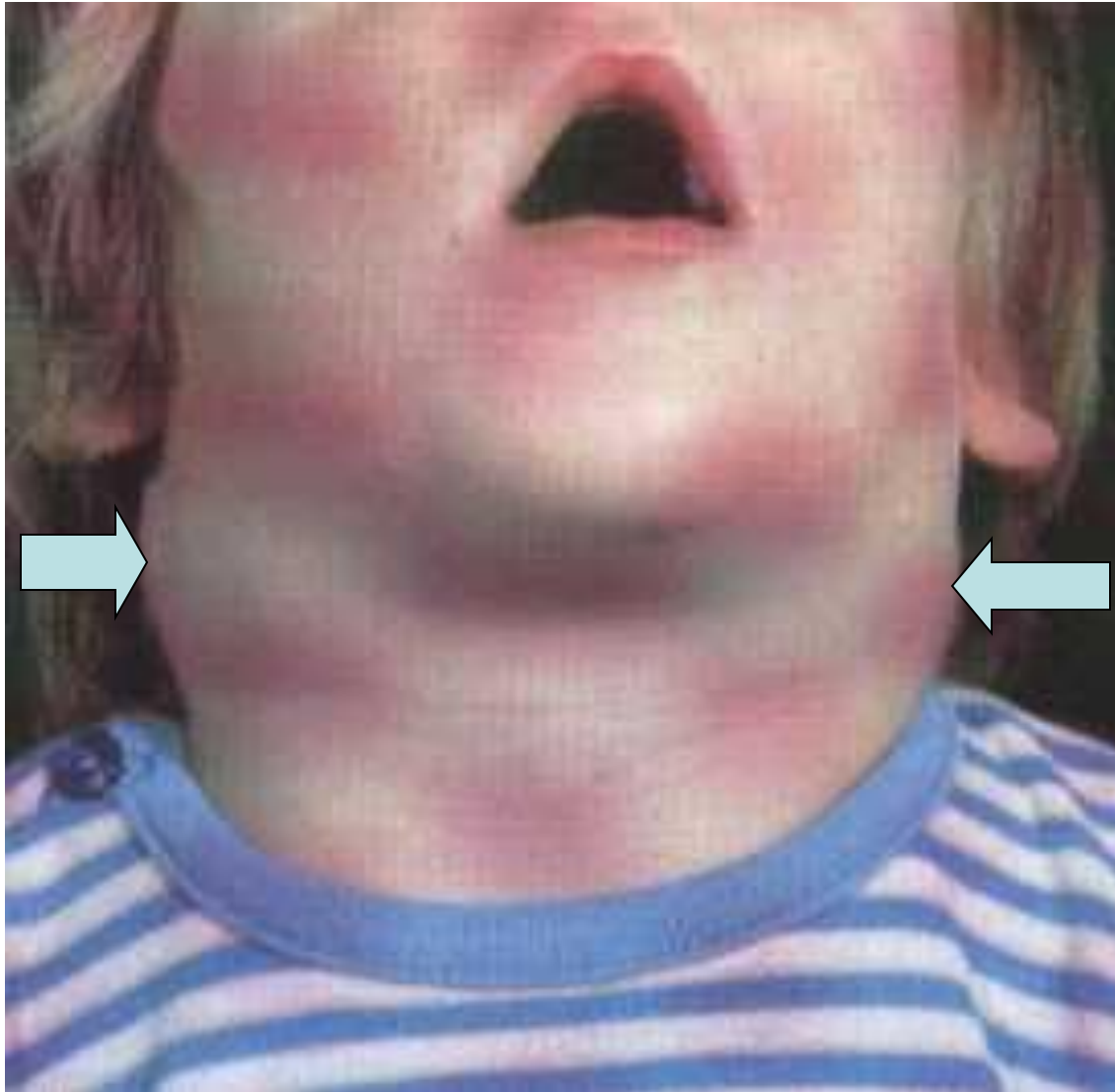

Lymphoma

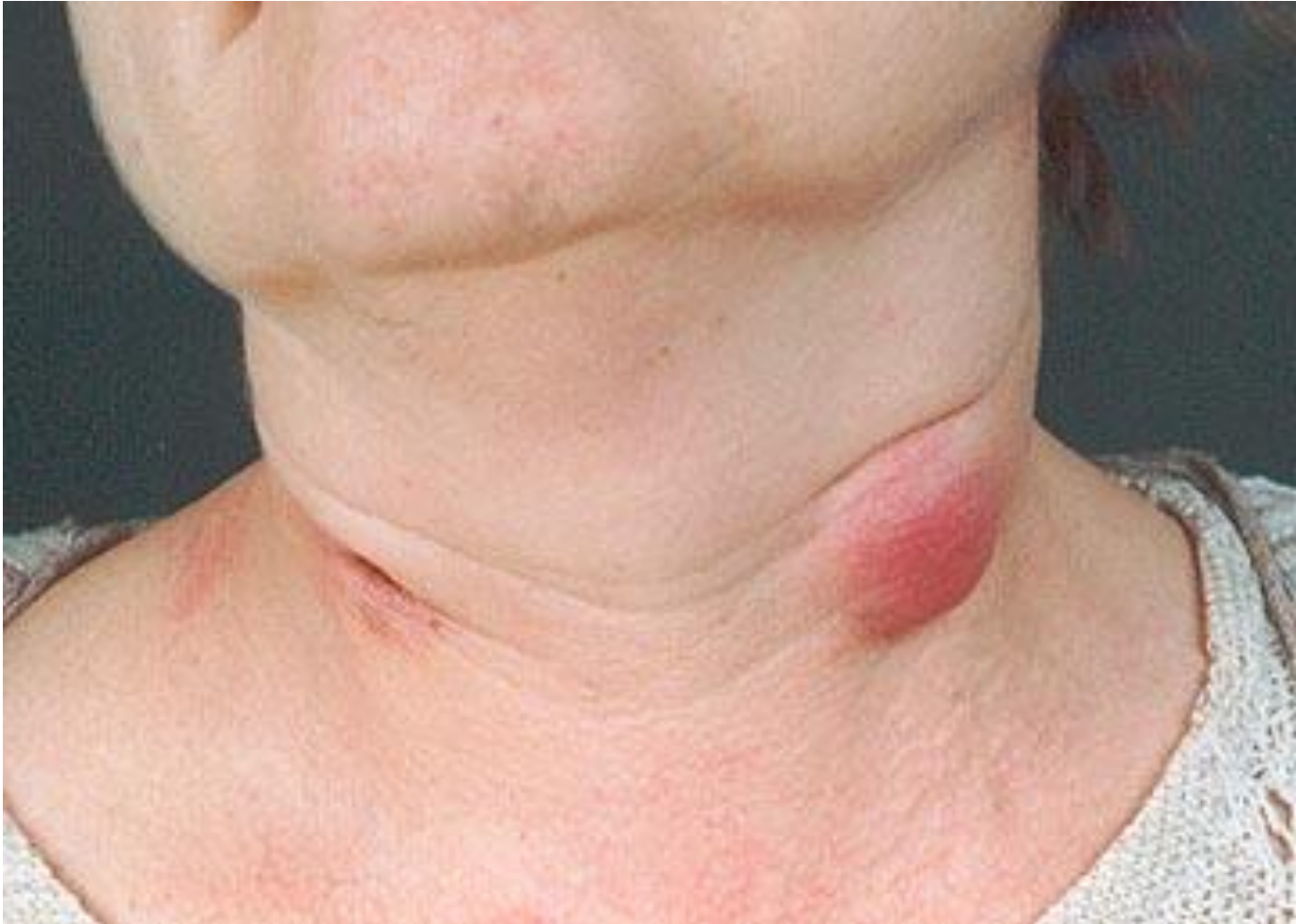

Row of
enlarged
lymph nodes

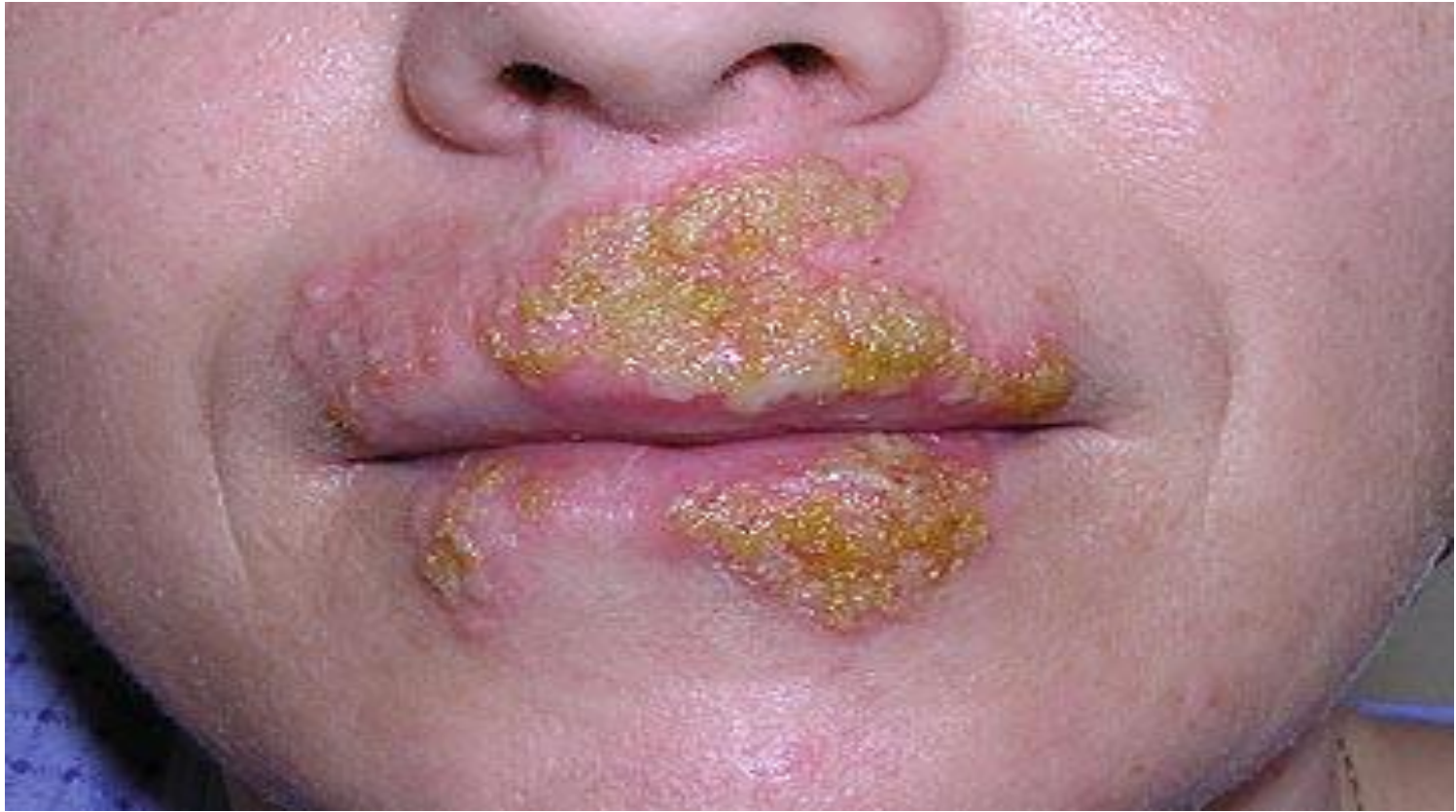ALL:Cervical Lymphadenopathy



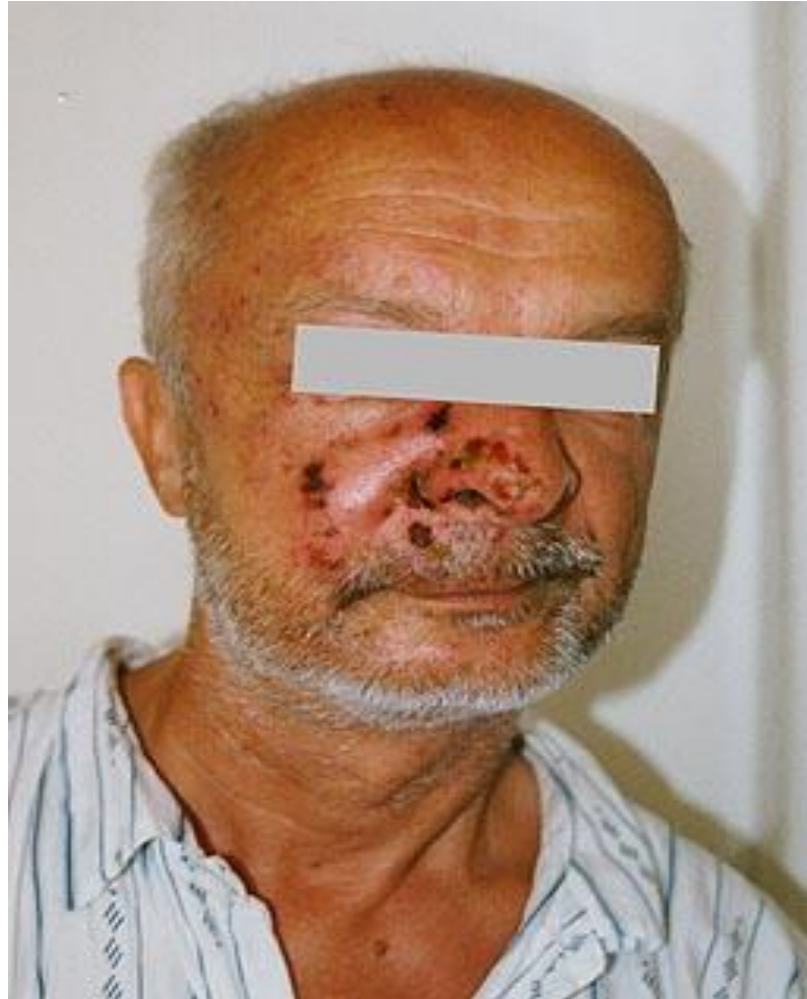tularemie



Herpes labialis



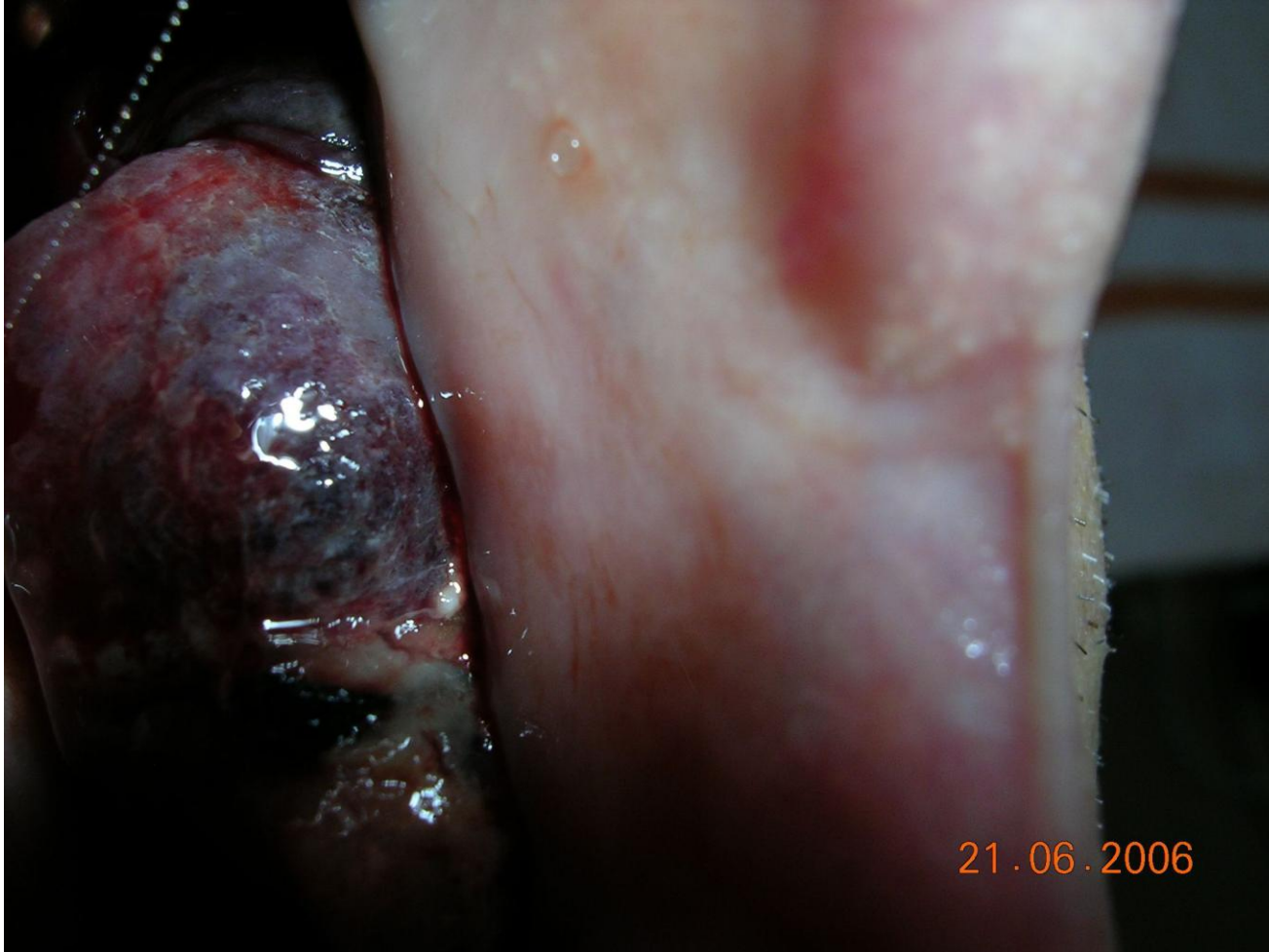Herpes zoster



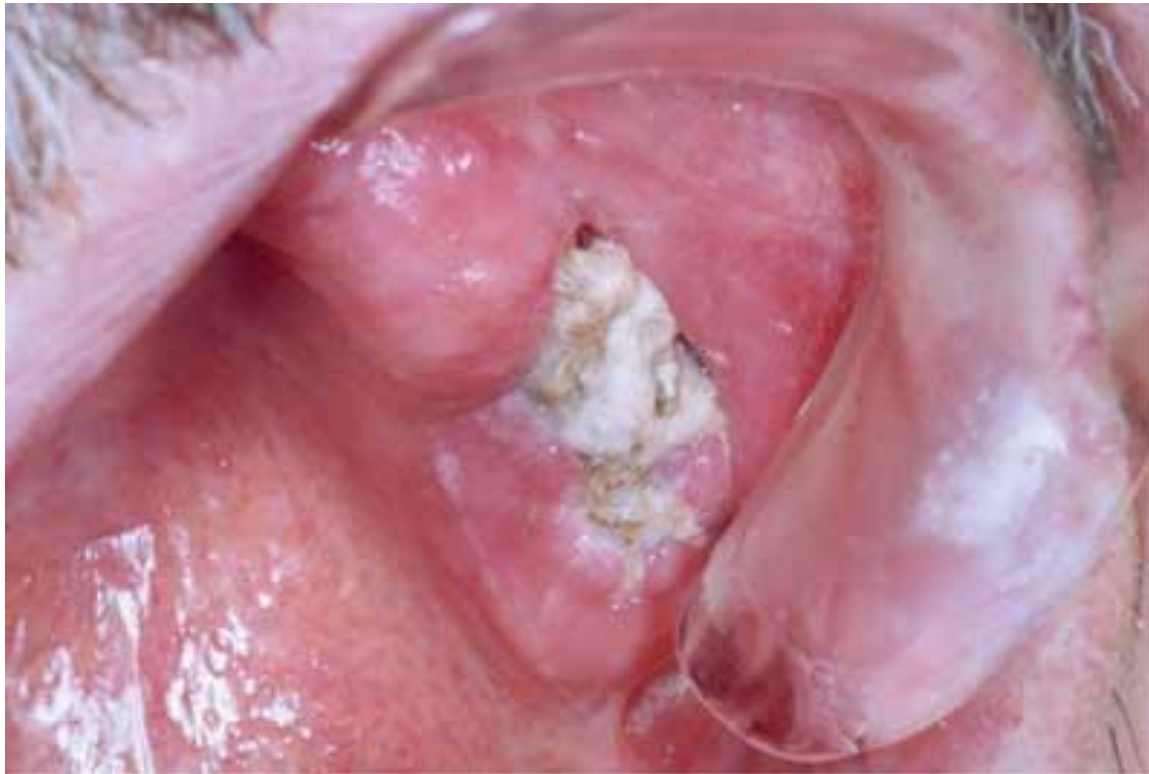Hematom tváře, tromocytopenie



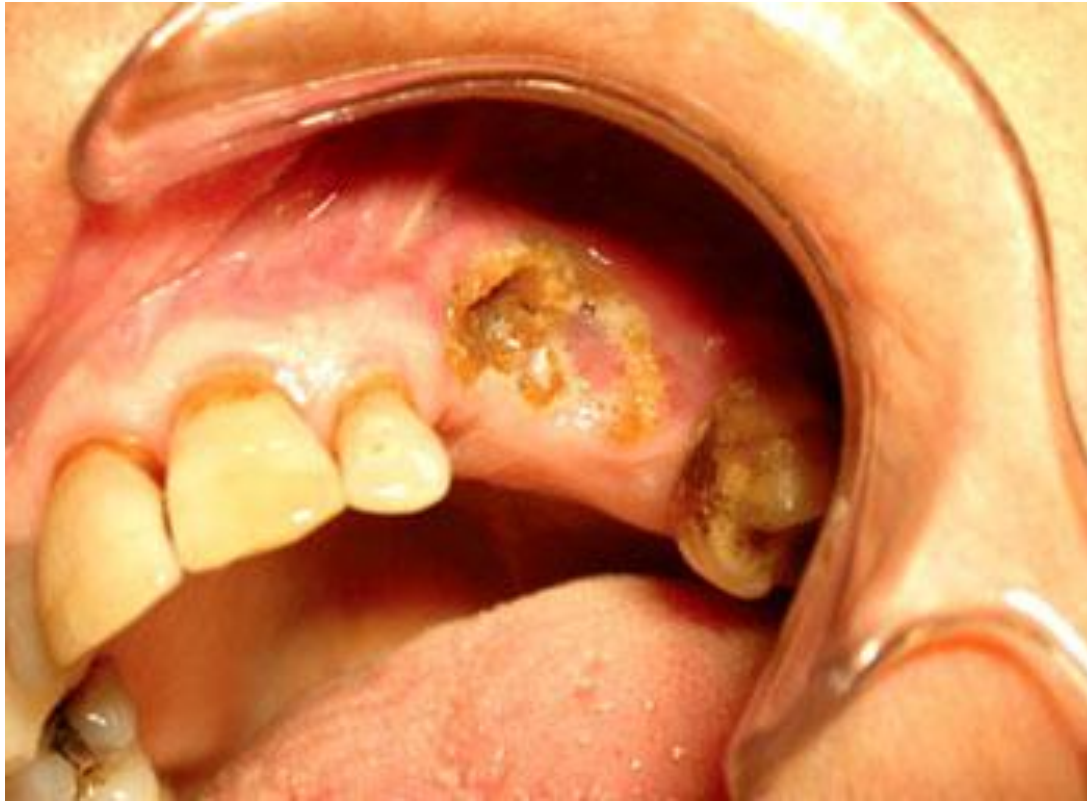Hematom v dutině ústní, tromocytopenie



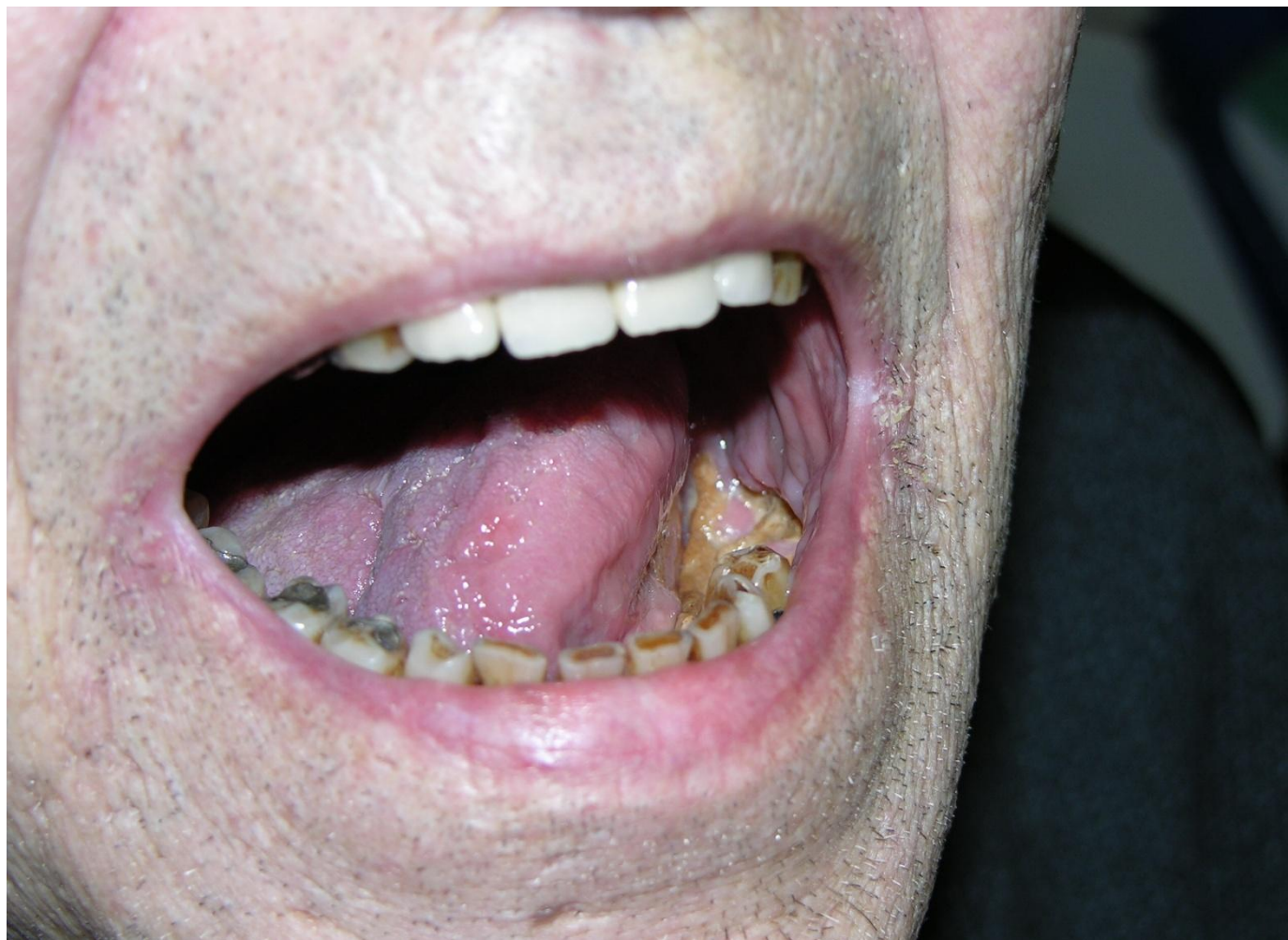Nekroza čelisti (po bisfosfonátu)



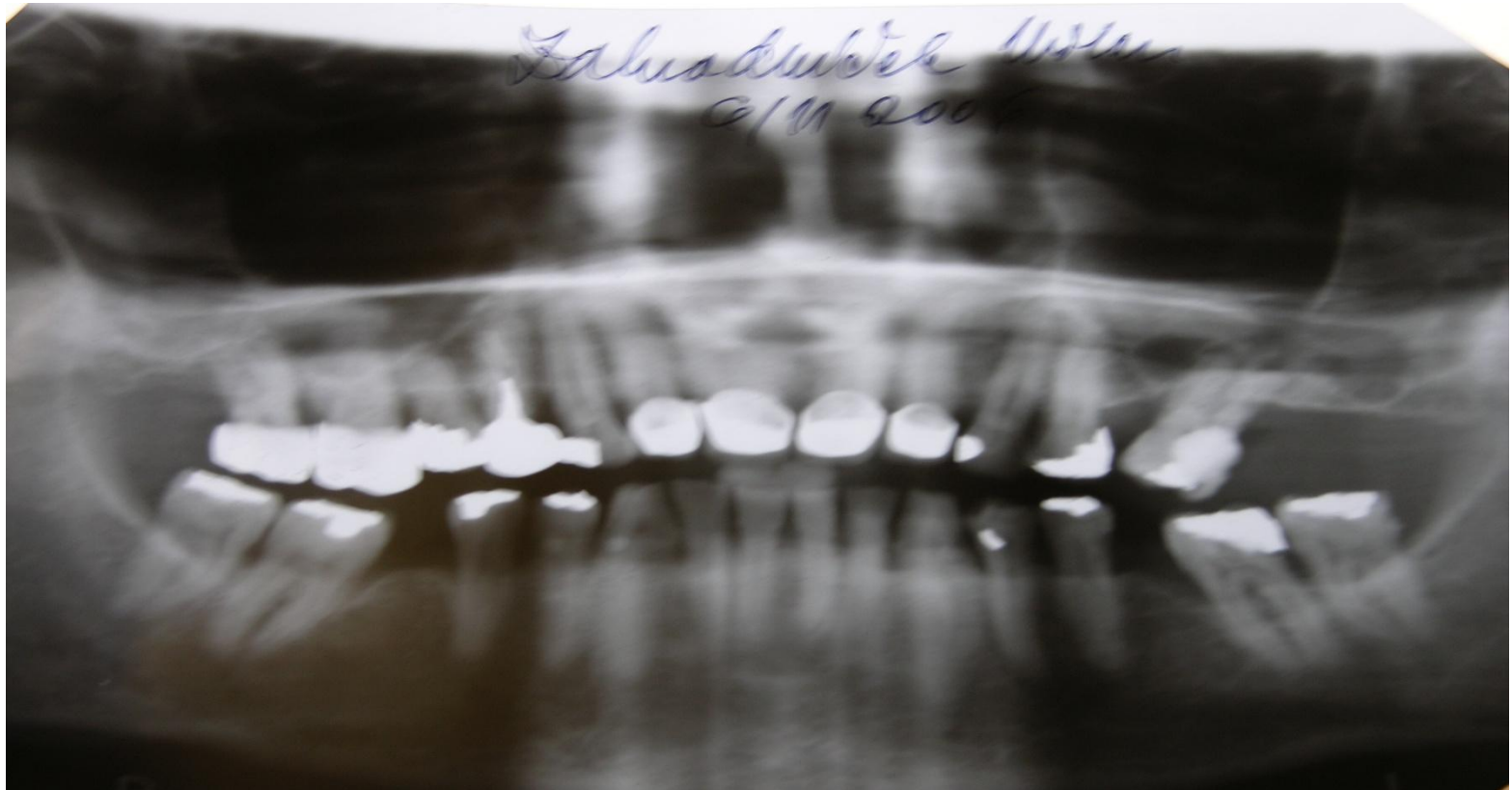
Nekroza čelisti , po bisfosfonatu



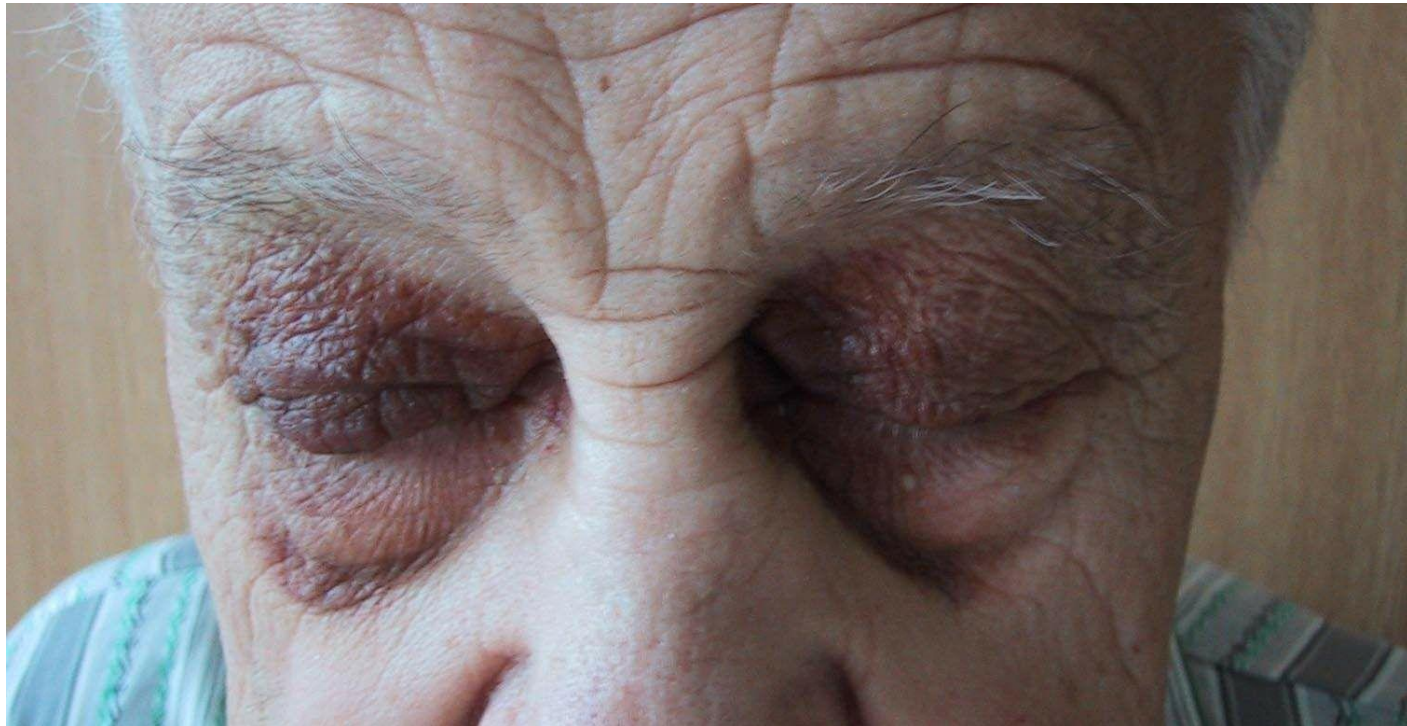Vs. nekroza čelisti, MM, (M.Z.)



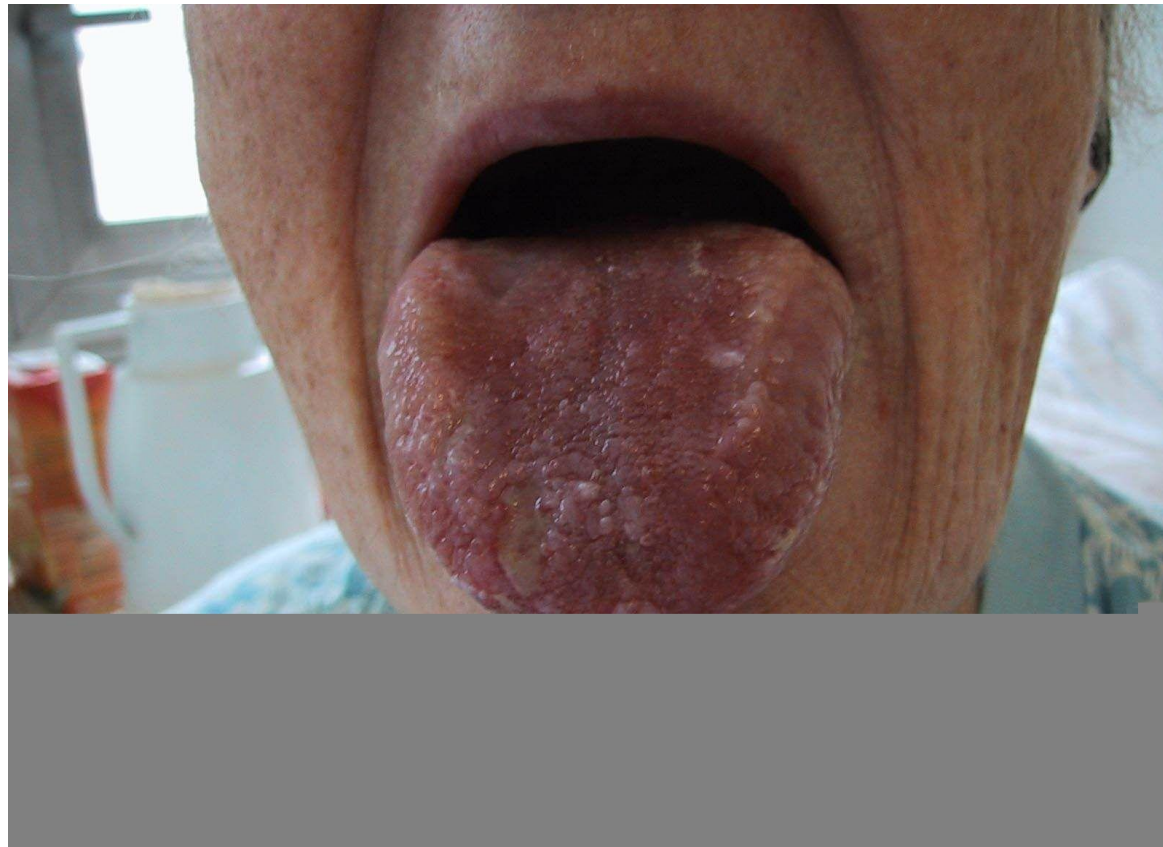Vs. nekroza čelisti, MM, (M.Z.)



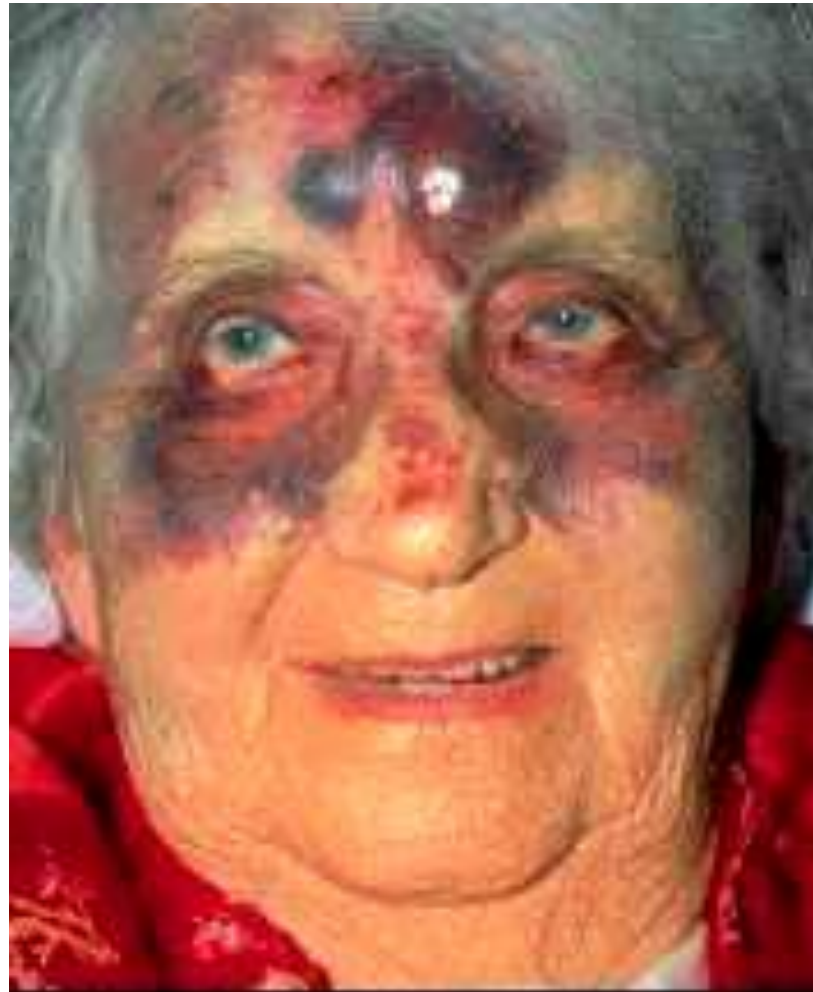Amyloidoza, purpura víček



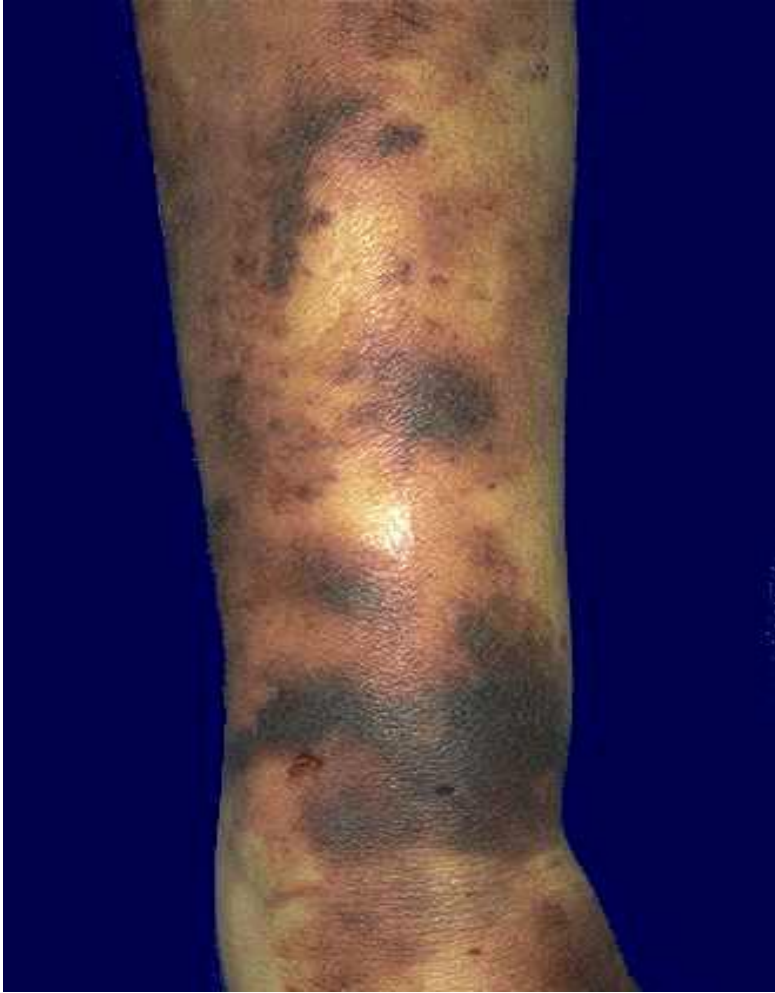amyloidoza



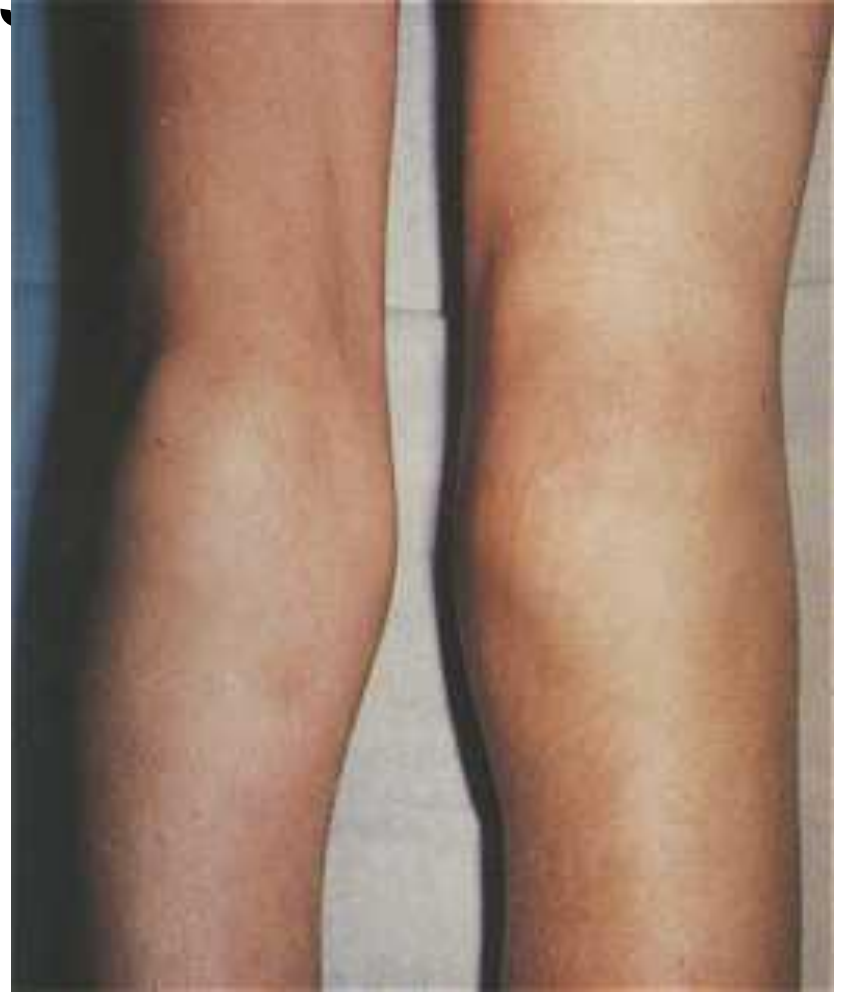MPS : E.T. Bleeding



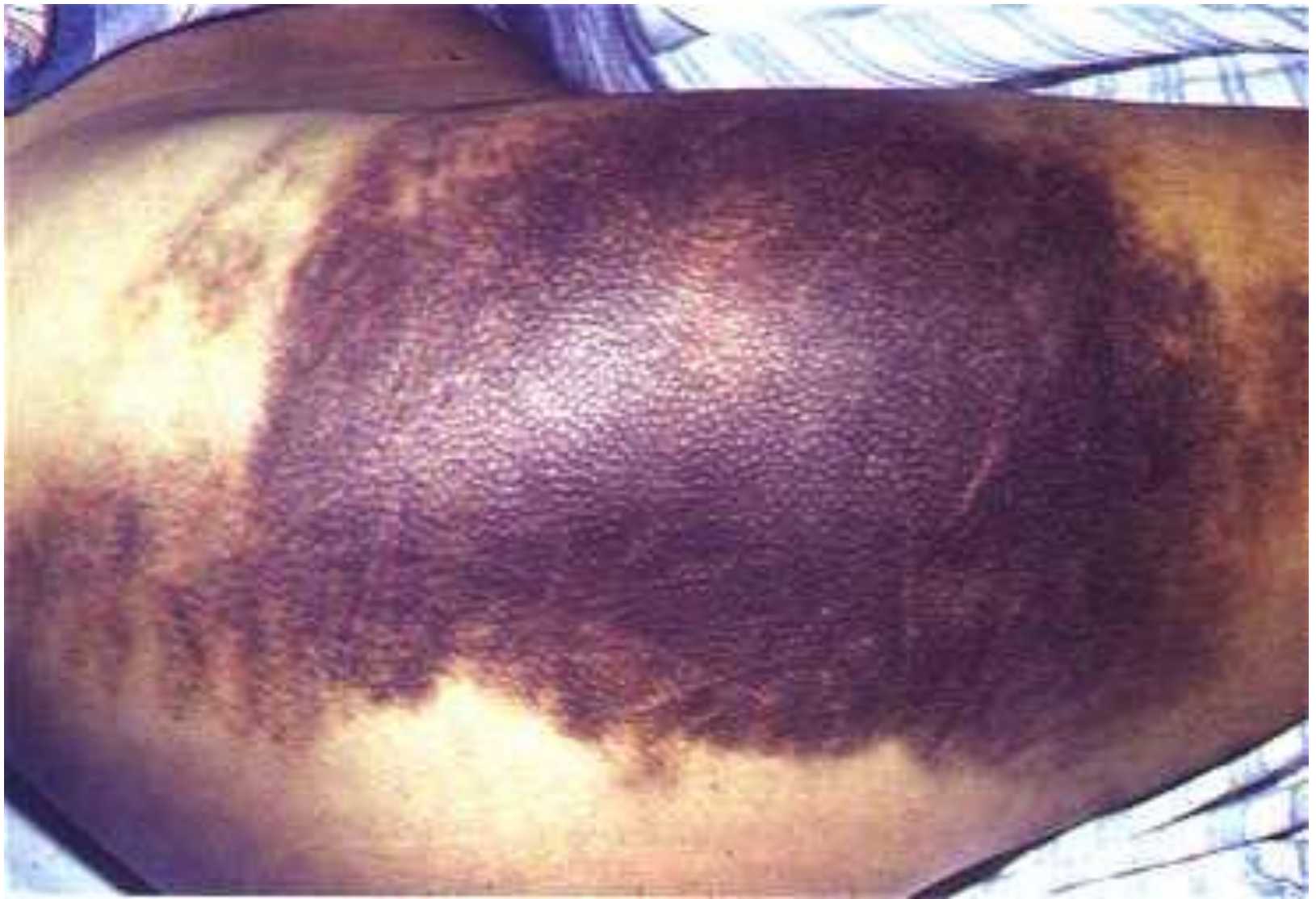Platelet Coagulation



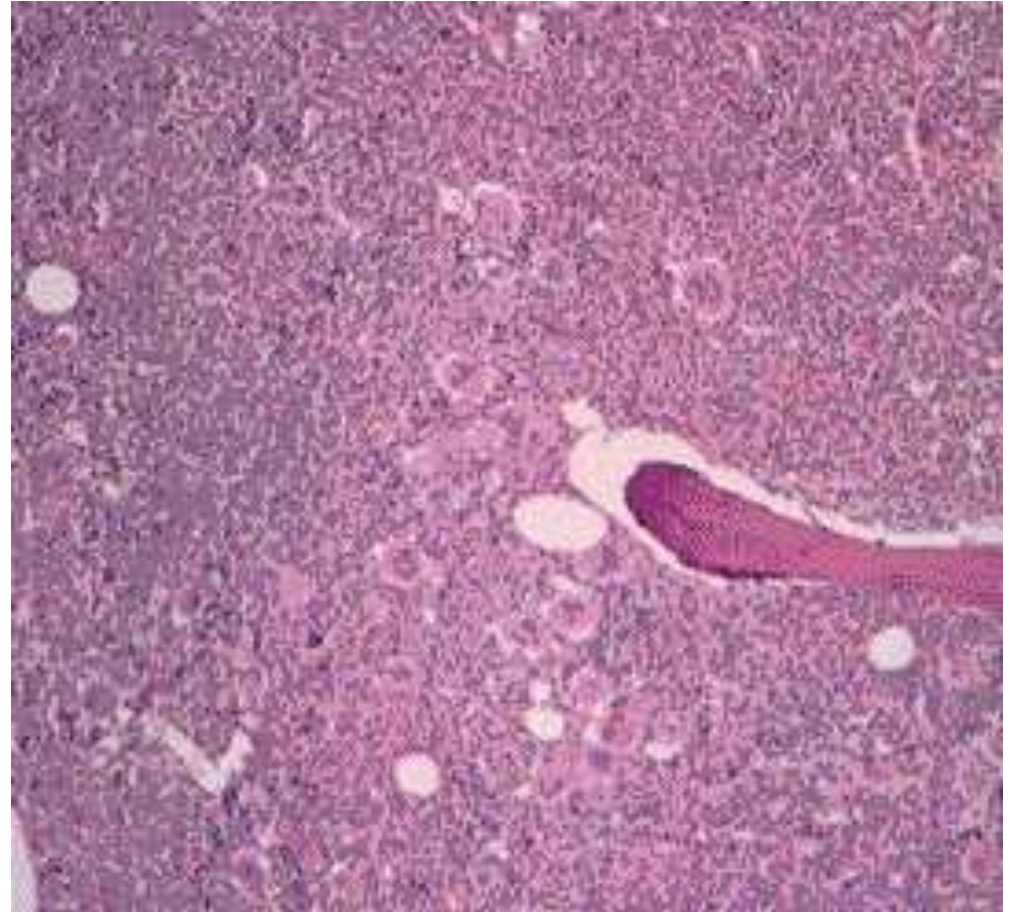
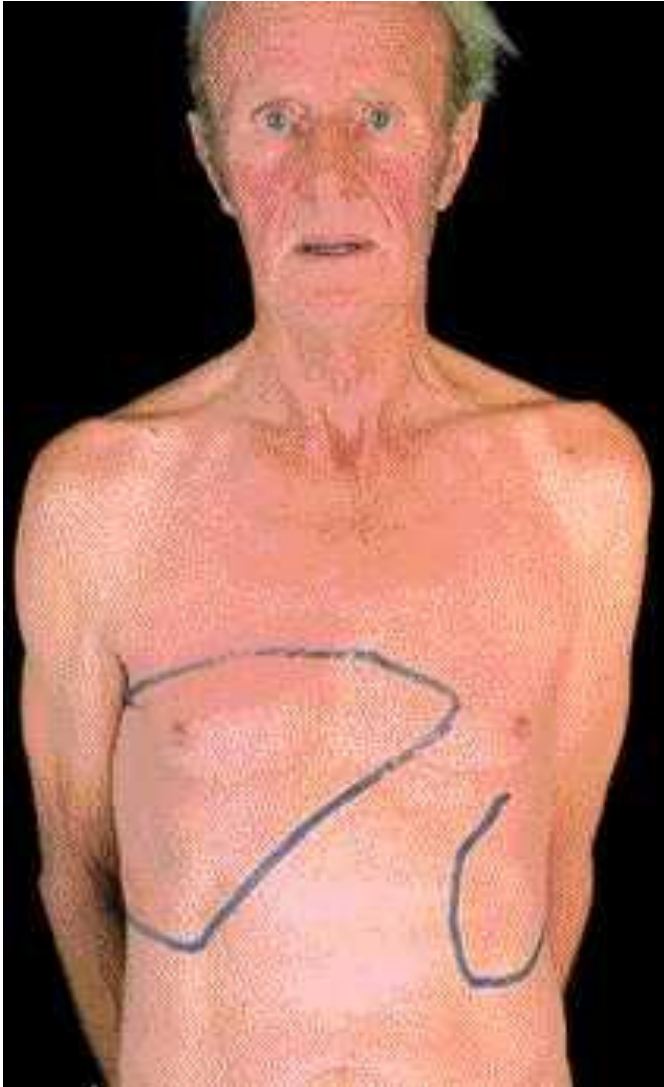
Petechiae, Purpura



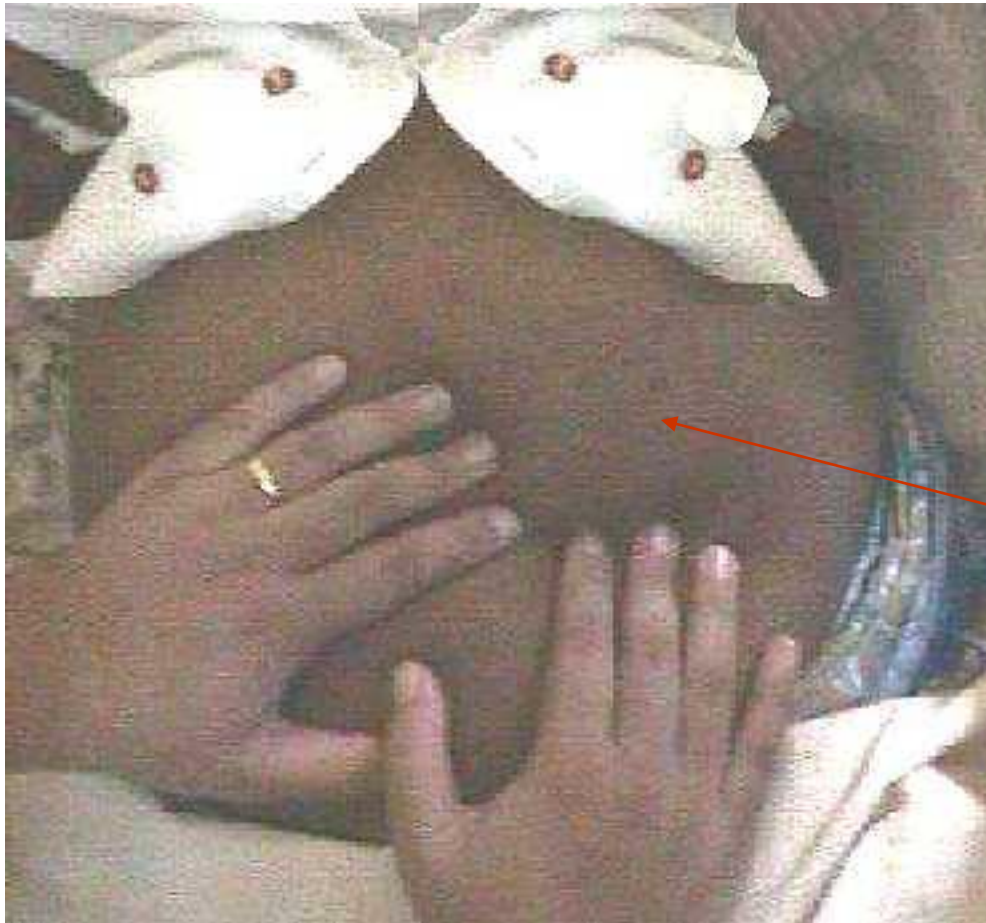Hematoma, Joint bl.



MPS - P. Rubra Vera (PV)



Splenomegaly



Spleen

MPS : M.F. Organomegaly

